

JASA

ISSN 2347-811X

Journal of the Association of Surgeons of Assam

JASA, Vol. 22, No. 1,

January-April, 2015

Editor:

Dr H. K. Dutta, MS,M.Ch.



Editorial Board Members

Dr. N.N. Das, Guwahati Dr. K. Bhuyan, Guwahati
Dr. D.K. Sarma, Guwahati Dr. AP Lal, Dibrugarh
Dr. M. Saha, Guwahati

Editorial Consultants

Prof. Rama Kant, Lucknow Prof. Andre Nicolus, France
Prof. N.C.Bhattacharyya, Tezpur Dr. S. Singhvi, New Delhi
Prof. Arjun Rao, USA Prof. M. Srinivas, New Delhi
Prof. K. Das, Bengaluru Dr. R.N. Majumdar, Guwahati
Prof. J. Ahmed, Dibrugarh Dr. D. Hazarika, Bongaigaon
Prof. A.C. Baro, Jorhat Dr. N. Das, Silchar

JASA

Journal of the Association of
Surgeons of Assam

Vol. 22, Issue No. 1
January-April, 2015

C O N T E N T S



• Obituary	3
• Doyens of Surgery	4
• Editorial : Dr. H.K. Dutta	5
Review Article :	
• Catheter related complications, its prevention and management Rajeev T. P, Debajit Baishya, Debanga Sarma, S. K. Barua, S. J. Baruah	6
• Consent in Surgical practice: An analysis Dr. R.C. Brahma, Dr. Swapan Deka Manindranath	14
Original Article :	
• Impact of stone clearance in patients with urinary stone disease and chronic kidney disease Prof. Rajeev T.P., Dr. Hrishikesh Bordoloi, Dr. Debanga Sarma, Dr. Sasanka Kumar Barua, Prof. Saumar Jyoti Barua, Dr. Puskal Kumar Bagchi	19
• Maternal nutrition and congenital malformation Dr. Mauchumi Baruah, Dr. H.K.Dutta, Sri D. Borbora	24
Case Reports :	
• Chronic umbilical sinus in an adult as a consequence of urachal remnant : a case report Dr. Nirmal Kumar Agarwal	28
• Ceroid Granuloma of the Extra Hepatic Billiary System : A rare entity causing obstructive jaundice Dr Gunabhi Ram Das, Dr Dipak K. Sarma, Dr. Rocket C. Brahma, Dr. Anuj K Sarma, Dr. David Pegu, Dr. Nilaksha Bhattacharjee	31
• Complications following forgotten DJ urinary stent: A case report Dr Rocket Chandra Brahma, Dr Sidhartha Sankar Konwar	35
• Chronic osteomyelitis of clavicle in an immunocompetent adult: a case report Dr. Bikash Jyoti Bordoloi, Dr. Pradip Kumar Baruah, Dr. Rajarshi Roy, Dr. Bikash Agarwal	38
• Journal Review:	41
• Association News:	44

OBITUARY



Dr. Satya Brata Dutta Choudhury

ASI membership No. 5456 (FL)

Date of Birth: 05.11.1933

Expired on: 24.02.2015

1. STOOD 10TH IN FINAL MBBS EXAM
2. DRCOG (LONDON)
3. FRCS (EDINBURG)
4. RETIRED PROF AND HEAD OF DEPARTMENT, SILCHAR MEDICAL COLLEGE, ASSAM.
5. SELECTED AS EMINENT SURGEON VIDE BOOK REFERENCES ASIA
6. PAST PRESIDENT OF ASSOCIATION OF SURGEONS OF ASSAM.

DOYENS OF SURGERY



Prof. M.A. Chowdhury

PROF. M.A. CHOWDHURY, a brilliant student since his school days joined Assam Medical College, Dibrugarh in the 3rd batch of MBBS. He passed out in 1954 securing 3rd rank. Subsequently he joined the department of Surgery at Assam Medical College as Registrar. He was the first student to join post graduate course in Surgery under Prof. Banerjee. He took Carcinoma esophagus as his thesis subject, but before he could complete it, he proceeded to the U.K. for his FRCS, which he obtained from the Edinburgh University. Upon his return from UK, Prof. Chowdhury joined back his alma mater initially as Assistant Professor, then he rose to become Professor and Head of the department of surgery, a position he held till his superannuation. He also served as the Principal cum Chief Supdt. of Assam Medical College & Hospital since 27.06.85 till 31.03.88.

Prof. Chowdhury had all the attributes of a great surgeon: clinical acumen, dexterity, courage and thoroughness. As a teacher, he was unconventional, yet a role model for his students. A great pioneer of original thinking in surgery, he infused in the minds of his students the acumen of a clinician. He never allowed his students to bypass a thorough and methodical clinical examination and he used to say "never be a slave of the laboratory". His bedside lectures were superb, so were his clinical rounds. He made the most difficult and challenging surgical procedures look simple and easy. He strictly followed the principles of anti-sepsis and asepsis in the operation theatre and often did not prescribe any antibiotic after routine surgery.

Vividly I remember meeting Prof. Chowdhury, for the first time in 1963, when I was a student of class IX at Dibrugarh Govt. High School. My father took me to him for some surgical problem. When he learned that I was the first boy of the class, he refused any consultation fee; rather he asked my father to take care of my studies suggesting that medical profession was a good choice. In course of time, he became a good friend of my father. Many years later, I joined his unit as an intern, and then as house surgeon and subsequently as Registrar. Working under him was the most cherished time of my life and this experience has changed the course of my life.

Apart from surgery, Prof. Chowdhury was a very knowledgeable person. His theory classes were full of interesting anecdotes, philosophical notes and historical accounts of important surgical innovations and used to stretch for two to three hours. He was also an accomplished Bridge player.

It is matter of pride that many of his students are now shining in their respective fields all over the world. Nothing can be a better tribute than this to this finest surgeon and a great teacher. May the Almighty rest his soul in peace.

Prof. G.M.S. Chowdhury
Ex-Professor of Surgery

Editorial

Innovations in surgery: a historical review

"The abdomen, the chest and the brain will forever be shut from the intrusion of the wise and humane surgeon." So opined Sir John Ericksen, Surgeon Extraordinaire to Queen Victoria in 1837. Today thousands of surgical procedures are carried out daily, many in the abdomen, the chest, or the brain.

Surgery, as one of the oldest and most respected fields, built upon continuous innovation, has a unique culture and deep tradition. It is the unsolved problem, or the repetitive failures of existing therapies that stimulate surgeons to find a better way. Throughout history, surgeons have been the most prolific medical device innovators. The first iteration of approach was described by Hippocrates in the 4th century B.C. Within his school on the island of Kos, he described the first rectal speculum, an enabling technology that supported subsequent endoscopic developments such as the pelvic speculum [1,2].

Not much changed until the advent of focused lighting. In 1805, Philip Bozzini, invented the Lichtleiter, a lighting apparatus supporting visualization of the bladder and rectum through mirror reflected candle-light [1]. This enabling technology supported critically important future advances in lighting. Antoine Jean Desormeaux built on Bozzini's external light source to create and present the first functional cystoscope in 1855, earning him the title the "Father of Endoscopy [3-5]. Not coincidentally, this period also saw the invention of functional esophagoscopy and hysteroscopy [6,7]. The combination of enabling technology and procedure stimulated an expanding period in endoscopic innovation with the development of multiple new technologies and a significant impact on patient care.

An increasing number of surgical leaders think that innovation may be the only way to maintain the quality of their profession. Johns Hopkins' first surgeon-in-chief, William Halsted, M.D., laid the foundation for surgery in the United States [8]. Dr. Halsted was dedicated to skill and technique and made many revolutionary contributions to the field of surgery, including pioneering the first lifesaving surgical treatment for breast cancer and developing new operations for intestinal and stomach diseases, gallstone removal, hernia repair and disorders of the thyroid gland.

In 1901, Georg Kelling introduced a cystoscope into a dog's abdominal cavity, performing the first laparoscopy [9]. Although Kelling's work generated much interest among the surgical fraternity,



the following 50 years were spent on refining the endoscopic techniques. During this period, a great deal of attention was focused on the rapidly expanding fields of cardiothoracic and trauma surgery. During the 1960s and 1970s, Kurt Semm helped rekindle interest and enable advances in surgical endoscopy by inventing devices for automatic insufflation, thermocoagulation, and endoscopic irrigation.

During the next few decades, a new period of surgical endoscopy expansion had begun. Modern minimal access surgery was borne out of vast experiences gained in arthroscopy for orthopedics and laparoscopy for gynecologic surgery. A French surgeon, Philippe Mouret, operated on a woman suffering from both a gynecologic disorder and gallstones in 1987. He turned the laparoscope upward and performed the first laparoscopic cholecystectomy [3]. Francois Dubois of Paris learned of the procedure and he began experiments in both animals and humans and presented his work at an academic meeting in Paris. Dubois worked with a French colleague, Jacques Perissat, to publicize efforts in laparoscopic cholecystectomy. Subsequent years saw rapid expansion of technology available for laparoscopy as well as surgeons interested in performing ever more complex operations.

However, the idea that large problems require large incisions so deeply dominated surgical thinking that there was little room to appreciate the advances of "key-hole" surgery. There are countless historical examples of the surgical community's reluctance to accept change. From the 1805 comment that Bozzini's *Lichtleiter* was a "magic lantern" to the 1992 Caversham Conference where the "tidal wave" of new technology was noted to be "threatening western health-care systems," the surgical community has been consistently antagonistic to innovators [10]. Doubts were raised as "surgical innovation is part of that threat" and "surgery needs to be on its guard against fashion[11]". These thoughts are not unreasonable. As Stirratt et al commented, "new surgical procedures must be tested, and that means clinical testing by mortality and morbidity, and psychologic and social testing by outcome for the individual patient and the community [11]. It may also be noted that laparoscopic cholecystectomy was not evaluated initially by randomized controlled trials but was propelled by anecdotes and case series [12].

Innovation is defined as the act of introducing something new or the use of a new idea or method [13]. In some instances, it is used synonymously with invention, although innovation is more precisely defined as something thought up or mentally fabricated. Importantly, no technology or its application is entirely new, as no inventor works within a vacuum [14]. All definitions of innovation involve both new ideas and an act of use or practice. The coupling of new ideas and hands-on use is also a central tenet of surgery, partially explaining the historical success of surgeons as innovators and the progress, which their innovation created. These new ideas may come in the form of technology, technique, or a combination. The process by which surgical innovation applies new ideas to "hands on" clinical needs is analogous to the process by which translational research applies basic research to clinical problems.



Research is also not the same as innovation. Advancement in the basic sciences represents critically important progress. This research contributes to the fundamental knowledge base and supports future invention. However, basic science research is not the same as innovation as it does not require application or intended use. The distance between the two can be thought of as the translational gap.

Surgeons have historically been idea generators and creative practitioners within their craft. Each clinical case offers unique challenges and requires a degree of creativity. Surgeons understand clinical needs and may anticipate future advances and opportunities.

Nevertheless, for a field that is proud of its innovative roots, and in fact, dependent upon them, we often are stingy in our praise for novel ideas and procedures. It is clear that personal characteristics of the innovator and acceptance of the surgical community are just as critical to innovation as technology and technique. It should be noted that the impetus for surgical innovation may be changing as surgical care and health care, as a whole, are managed with fiscal performance as at least one primary outcome measure.

Dr. J.H.K. Dutta

References:

1. Rosin D. History. In: Minimal Access Medicine and Surgery. Oxford: Radcliffe Medical, 1993:1-9.
2. Litynski GS. Endoscopic surgery: the history, the pioneers. World J Surg. 1999;23:745-753. [PubMed]
3. Gorden A. The History and Development of Endoscopic Surgery. London: Saunders, 1993.
4. Lau WY, Leow CK, Li AK. History of endoscopic and laparoscopic surgery. World J Surg. 1997;21:444-453. [PubMed]
5. Desormeaux A.J. De l'Endoscopie, instrument proper a éclairer certaines cavités intérieures de l'économie. In: Compte rendu des Séances de l'Academie des Sciences. 1855.
6. Bevan L. The oesophagoscope. Lancet. 1868;1:470.
7. Pantaleoni D. On endoscopic examination of the cavity of the womb. Medical Press Circular, 1869:26.
8. Cosgrove DM. The innovation imperative. J Thorac Cardiovasc Surg. 2000;120:839-842. [PubMed]
9. . Kelling G. Die Tamponade der Bauchhöhle mit Luft zur Stillung lebensgefährlicher Intestinalblutungen. Med Wochenschr. 1901;48:1480.
10. Stirrat G, Ramsay B. Surgical innovation under scrutiny. Lancet. 1993;342:187-188. [PubMed]
11. Stirrat G, et al. The challenge of evaluating surgical procedures. Ann R Coll Surg Engl. 1992;74:80-84. [PMC free article] [PubMed]
12. Banta HD. Minimally Invasive Therapy (MIT) in Five European Countries. Amsterdam: Elsevier, 1993. [PubMed]
13. Jones JW, McCullough LB, Richman BW. Ethics of surgical innovation to treat rare diseases. J Vasc Surg. 2004;39:918-919. [PubMed]
14. History of Technology. Encyclopaedia Britannica, 2004.



Rajeev T. P¹
Debajit Baishya²
Debanga Sarma³
S. K. Barua⁴
S. J. Baruah⁵

Dr. Rajeev T. P.
Professor
Department of Urology
Gauhati Medical College and Hospital
Bhangagarh
Guwahati, Assam.
Pin - 781032.
Email - rajeevtpuro@gmail.com



Catheter related complications, its prevention and management

ABSTRACT

Establishment of urinary tract drainage is a basic skills required by all medical professionals. It is a simple procedure and most widely used in day to day life. Use of indwelling urinary catheter can lead to various complications most commonly urinary tract infection. These complications can result in prolong hospitalization, additional hospital costs, morbidity and mortality. This article aims to give a basic understanding about the indications of catheterization, proper technique of catheterization, various catheter related complications, its prevention and to tackle these complications.

Key Words : Catheter; Trauma; Complication

Introduction

Instruments to drain the urinary bladder are among the most ancient medical devices in the historical record. The earliest descriptions of a urinary catheter can be found in the Hippocratic text *On Diseases* (400 BC), in which bladder drainage was considered a basic skill in the armamentarium of Greek physicians. The practice of bladder catheterization to permit urine drainage also found in India, Egypt, and the Byzantine and Roman empires. In Avicenna's *Canon of Medicine*, mentioned urethral catheterization as a means to deliver intravesical therapy.

Early catheters include hollow tubes made of bronze, paper, animal hide, cloth soaked in wax and lead. In the 16th century, Ambroise Pare used catheters made of silver, brass, and copper. In the early 18th century, natural rubber was first used and the coudé tip was introduced by Mercier. The self-retaining balloon catheter was introduced in the 20th century by Foley, leading the way to permit development of catheters of synthetic materials with specialized coatings and drug-eluting properties.

Indication of catheterization

The common indications for the use of a bladder catheter can be broadly divided into two main categories:

- To obtain drainage
 - To allow the instillation of diagnostic or therapeutic agents.
- 1) The relief of acute or chronic urinary retention due to either bladder outlet obstruction or neurogenic bladder dysfunction is the most common indication for urethral catheterization (UC).
 - 2) To monitor urinary output.
 - 3) Urinary diversion by a catheter is used to allow healing after lower urinary tract surgery/trauma

- 4) To evacuate the bladder when the urine contains particulate matter, especially in combination with simultaneous irrigation (post transurethral resection, clot/purulent material evacuation).
- 5) Collection of microbiologic clean urine (uncooperative patients because of age or mental status or co morbidities that prevent voluntary voiding)
- 6) Measure postvoid residual urine volume samples for diagnostic purposes.
- 7) Urethral catheterization is also used to provide access to the bladder for urinary tract imaging studies such as cystography, which requires the instillation of radiographic contrast material.
- 8) Urethral catheterization with a pressure monitoring catheter is used during urodynamic testing for physiologic assessment of voiding function.
- 9) It is also used to allow instillation of pharmacologic agents for local therapy of some bladder pathologies such as chemo/immunotherapy for transitional cell carcinoma (mitomycin, bacillus of Calmette Guerin), interstitial cystitis (dimethyl sulfoxide), and intractable hematuria (e.g., alum, formalin instillation).

Though catheterization is a simple day care procedure there is various catheter related complication which may lead the patient to morbidity. A correct way of catheterization prevents most of these complications. So we will shortly discuss here the catheterization technique, catheter related complications, its prevention and how to tackle it.

Technique of Catheter Insertion

A clinical history including allergies, urologic pathology, previous urethral surgeries and catheterization attempts should be taken before catheterization. The patient should be in the supine position at a comfortable height for the physician. In female patients a "frog-leg" position is most suitable. Catheterization should be carried out in a sterile fashion with antiseptic preparation and draping of the patient's meatal and genital area, the catheter's retention balloon should be tested. 2% xylocain gel of 20 to 30 mL instil over 3 to 10 seconds and left indwelling a minimum of 10 minutes provides less traumatic catheter passage and reduce patient discomfort.

After sterile skin preparation and draping, grasp the shaft of the penis with the nondominant hand

(which is now regarded as contaminated) and hold the penis at a 90-degree angle or perpendicular to the patient. This maneuver eliminates the distal or pendulous urethral curvature. Insert the lubricated tip of the catheter into the urethral meatus and gently but firmly continue to advance the catheter for 7 to 10 cm, while simultaneously bringing the shaft of the penis to the horizontal plane or parallel to the patient. Continue to advance the catheter, while expecting to feel a slight increase in resistance as the membranous urethra (external striated sphincter) is traversed. Once the entire length of the catheter has been introduced (up to the juncture of the connector or to the two-way bifurcation), wait for spontaneous urine passage that confirming proper placement of the catheter. If spontaneous drainage of urine is not seen, gently press on the patient's suprapubic area. If despite this maneuver no drainage occurs, slowly instill 20 mL of saline using a catheter-tipped syringe into the drainage port of the catheter and then slowly aspirate the fluid instilled to clear any obstruction of the catheter side hole by lubricant or other material. If the catheter is in the bladder, fluid should be aspirated without resistance. If the catheter is still within the urethra, the negative pressure produced during aspiration will cause collapse of the urethral wall and will not permit the return of the instilled fluid. Only when the position of the catheter has been verified should the retaining balloon be inflated, with the amount of fluid indicated on the catheter. Sterile water is the preferred solution for balloon inflation. The catheter should be attached to a sterile closed bag system and bag should be placed below the level of the bladder to encourage one-way gravity flow with the tubing as straight as possible and avoiding kinks that might impair drainage that increase the chance of UTIs in up to one third of the patients. The exception to this is in patients with acute urinary retention with significant bladder distension in which rapid bladder drainage might precipitate decompression-induced hematuria or "ex vacuo hematuria." In these patients the catheter should be intermittently clamped and released to permit gradual bladder decompression over 30 to 60 minutes. If the patient is uncircumcised, at this point return the foreskin to its normal reduced position to avoid paraphimosis. Secure the catheter to the patient, allowing for a normal range of motion and without tension, using adhesive tape.

In infants and children younger than 3 years of age, when the normal foreskin adhesions have not yet involuted, simply align the preputial opening with the meatus to assist catheter insertion.

In female patients, after antiseptic preparation and sterile draping, use the nondominant hand to spread

the patient's labia (now considered contaminated) to reveal the urethral meatus. After lubrication, insert the tip of the catheter and gently advance using a slightly downward direction, until about half the length of the catheter has been inserted. Check for urine return and activate the anchoring mechanism if used.

Difficulties during female catheterization may be encountered for several reasons including the inability to locate the urethral meatus due to obesity and age-related changes and less frequently to strictures (postsurgery, radiotherapy, neoplastic causes). In the obese patient, the use of one or more assistants to provide labial retraction or the use of stirrups can be helpful. In the case of postmenopausal vaginal atrophy or other conditions resulting in the urethral meatus receding into the introitus, following measures can be taken. Holding the index and middle fingers of the nondominant hand together, slowly slide posterior along the introitus until the urethra. Using the dominant hand, pass the catheter along the groove made by the fingers (this serves a dual purpose-it creates a posterior border with the fingertips and provides a guide for the catheter). As the catheter tip crosses the meatus, it can be felt with the fingertips, thus ensuring proper placement. A second maneuver is to use a vaginal speculum to aid in the retraction and fixation of the introitus. Finally use a coudé tip catheter angled upward and gently slide the tip along the anterior vaginal wall in the midline, until it enters the meatus, and then advance into the bladder.

In female children the correct identification of the urethral meatus is essential to avoid unnecessary catheter contact with the sensitive introitus, leading to discomfort and possibly loss of cooperation by the child. The meatus is just above the superior margin of the introitus and frequently hidden by the superior portion of the hymen. Gentle downward pressure on the upper aspect of the hymen with a cotton ball may allow visualization of the meatus. Failing this maneuver, the catheter tip should be inserted just above the hymen in the midline.

Catheter related complications, its prevention and how to tackle it

1) UTI

It accounts for 40% of all nosocomial infections. Urethral catheters are responsible for up to (80%) of UTIs in the hospital setting [1].

Risk factors for CAUTIs (catheter associated UTI) include:

- Patients requiring more than 6 days of catheterization,

- Female gender,
- Active nonurinary infection sites,
- Pre existing medical conditions,
- Malnutrition,
- Renal insufficiency,
- Catheter insertion other than in the operating room having drainage tubing or bag elevated above the level of UB [2, 3].

Prevention of CAUTI

- Avoidance of unnecessary catheterization,
- Atraumatic technique of insertion,
- The use of a closed collection circuit,
- The use of aseptic technique [4].
- The application of antibiotic coatings (nitrofurazone and minocycline/ rifampin coatings), silver alloy onto catheter surfaces and the concept of drug elution reduces the incidence of asymptomatic bacteriuria [5-7].

But the routine use of catheter coatings is currently not supported by the available literature.

Not help to prevent UTI:

- The use of antiseptic gels or irrigations of the bladder or collection bag,
- Catheter clamping, or antireflux valves have not been shown to prevent CAUTIs [8, 9].

How to tackle CAUTI:

Patients with indwelling catheters should be treated only if they become symptomatic (e.g., febrile). Urine cultures should be performed before initiating antimicrobial therapy. The antimicrobial agent should be discontinued within 48 hours of resolution of the infection [10].

If the catheter has been indwelling for several weeks, encrustation may shelter bacteria from the antimicrobial agent; therefore the catheter should be changed.

When a catheter is to be removed and there is a high probability of bacteriuria or the dipstick test is positive, a culture should be obtained 24 hours before removal [11].

If the probability is low or the dipstick is negative, a culture may not be necessary. The patient should be started on empirical antimicrobial therapy such as TMP-SMX or a fluoroquinolone just before decatheterization and maintained on therapy for 2 days.

A post-therapy culture should be obtained 7 to 10 days later to confirm the eradication of the bacteriuria.

2) Inability to remove the catheter from the bladder

A frequent encountered problem, is the inability to remove a straight Foley catheter, this may due to

- Encrustation,
- Entrapment by sutures, or
- Inability to disengage/deflate the retaining balloon.

The latter problem may be due to a faulty valve, inflation channel blockage, or rarely crystallization within the balloon.

If the catheter has been indwelling for a long period of time, encrustation should be considered and imaging studies (plain film or ultrasound) will be confirmatory.

Prevention

- Sterile water is the preferred solution for balloon inflation as electrolyte or glucose-based solutions can precipitate and occlude the tubing and valve mechanism.

- In case of long standing catheterization catheter must be changed 3-4 weekly to prevent encrustation

How to tackle it

- In many instances the encrustation is easily dislodged with gentle traction on the catheter.

- For more significant encrustations, one can consider using a semirigid ureteroscope and the holmium:YAG laser to remove the stone fragments.

- If the catheter is quite rigidly fixed and in the setting of recent bladder or prostate surgery, semirigidureteroscopy along the catheter and using the holmium:YAG to release the suture have also been described.

- Because the suture materials used in bladder and prostate surgery are often absorbable, waiting for suture dissolution is another option.

- An inability to deflate a Foley balloon can be managed using a step wise approach.

- a) One should first attempt to place another 1 to 2 mL of fluid in the balloon to ensure normal balloon contour. Next step is to cut the inflation port. If the valve is the source of the problem, balloon deflation should then occur.
- b) Perforation of balloon can be done bed side by overinflating the balloon to the level of perforation and also by chemical instillations (e.g. ether) for intravesical rupture of the balloon, but these procedures not recommend as these maneuver may be painful to the patient, may cause bladder injury and retention of the

balloon fragments, can cause chemical cystitis, UTI, stone formation etc.

- c) Insertion of a surgical steel wire (24 or 28 gauge; often included as an obturator for small-caliber ureteral catheters) or the stiff end of a 0.035-inch hydrophilic-coated guidewire through the valve inflation lumen bypasses the site of obstruction or creates a small perforation of the balloon can be done.
- d) Should none of these maneuvers be successful, the use of ultrasound-guided needle puncture of balloon can be done with a long spinal needle (22 gauge) using either a transrectal, transvaginal, or suprapubic surface probe.
- e) If all other maneuver failed retained catheters can be removed with open surgery..

4) Other complications

- Hematuria,
- Urethral injury
- Urethral and meatal strictures,
- Urethral perforation, and allergic reactions including anaphylaxis
- Malignant neoplasms (2.3% to 10%),
- Stone formation (46% to 53%),
- Bladder neck and urethral erosions.

Prevention

- a) As a general rule, catheter size should be the smallest size that can accomplish the desired drainage (i.e., 12 to 14 Fr for clear urine and 20 to 24 for thick pus or blood-filled urine).
- b) Silicone catheters are indicated when there is rubber/latex sensitivity or allergy and are particularly suited for patients requiring a longer period of indwelling time.
- c) Every catheter should be generously coated with sterile lubricant before insertion decrease chance of urethral injury.
- d) Only when the position of the catheter has been verified should the retaining balloon be inflated.
- e) Secure the catheter to the patient, allowing for a normal range of motion and without tension, using adhesive tape.
- f) In cases where long term catheterization requires clean intermittent catheterization reduce incidence of malignant neoplasms,

stone formation, and bladder neck and urethral erosions.[12, 13]

- g) In cases of long term catheterization regular upper and lower tract imaging, cystoscopy and random biopsy are require in prevention and early diagnosis of malignant neoplasms, stone formation

How to tackle it

Hematuria, urethral injury is occurs in difficult catheterization (most commonly due to prostatic growth, urethral stricture, bladder neck contracture, false passage from previous urethral instrumentation, phimosis or urethral calculi).

Using adequate urethral lubrication and a 16- or 18-Fr coudé tip silicone catheter is often successful in patients with BPH.

If multiple previously unsuccessful attempts have been made and urethral trauma is suspected due to the appearance of a bloody urethral discharge, a false passage or a stricture is likely. A single atraumatic attempt can be made using a 12-Fr silicon/straight or coudé tip catheter. If this maneuver is unsuccessful then depend upon the available facility flexible cystoscopy can be done, allowing a direct visual approach that can be both diagnostic and therapeutic and minimizes the risk of further urethral injury. Under direct vision, the area where the false passage was created or the site of stricture formation is identified and an attempt is made to identify the true urethral lumen. Once identified, a 0.035 in Teflon-coated guidewire (e.g., Bentson type) is passed along the urethral lumen and into the bladder and urethral dilation may be done in case of a tight urethral stricture or bladder neck contracture over the guidewire. Once the urethral lumen is of adequate diameter to permit placement of the catheter , a Councill catheter, which can be advanced over the guidewire into the bladder, is selected.

If flexible instruments are unavailable and a urethral stricture is suspected, then a blind technique although less desirable, can be used. This technique involves using filiforms and followers The first step is to pass a small female filiform catheter. In many cases the initial filiform will frequently end up entrapped in the stricture membrane or in the false passage, rather than following the true lumen. Insertion of additional filiforms will then fill the false passage or stricture membrane until one is successfully directed into the true lumen. Once a filiform is successfully passed, male sections (followers) of increasing size are attached to the filiform to permit sequential dilation of the urethra.

Once dilation to at least 14 to 16 Fr has been achieved, a 12- to 14-Fr catheter is then passed.

Alternatively, one can blindly pass a Councill catheter to the point of resistance and then attempt to advance a hydrophiliccoated guidewire. If guidewire advancement seems to go easily, a 5-Fr open-ended or angled ureteral catheter can be advanced over the wire to permit urine drainage and confirm bladder positioning. Once bladder positioning of the guidewire is assured, urethral dilation can be performed over the guidewire followed by Councill catheter placement.

If none of these techniques are feasible, a suprapubic catheter should then be inserted

Complication related to feeding tube

Feeding tube is routinely used by most hypospadiologist as well as in infants and small children. But because of their stiffness and length some rare but morbid complications may occur over and above the above mentioned catheter related complications eg. ischemic ulcers, urethral strictures, and knotting in the bladder. Infant feeding tube knotting is a very rare event [13]. It gets knotted when excessive length of flexible catheter is inserted in the bladder and forms a loop; subsequently as the catheter is withdrawn a knot can form and tightens on withdrawal leads to impaction of the catheter.

Prevention

It is best to prevent this problem by totally avoiding the use of infant feeding tube or by introducing only short length of feeding tube to drain the bladder. A 6-10F Foley's catheter may be a better option. A high index of suspicion is required to diagnose knotting of infant feeding tube when it cannot be withdrawn easily. This will prevent traumatic urethral injury due to forcible removal and subsequent risk of urethral stricture.

How to tackle it

Removal of infant feeding tube has been tried in many ways-

- Manual removal of catheter with gentle traction under local/general anesthesia
- Infant feeding tube may be uncoiled by passing a guide wire through the infant feeding tube and straightening it, but may fail if the knot is too tight.[15].
- Open or laparoscopic supra pubic cystostomy and removal of the feeding tube

Conclusion:

Though catheterization is a simple procedure, catheter related complications may lead to various co morbidities. These complications can be prevented by

well training of our medical and paramedical persons for safe catheterization in a proper aseptic and antiseptic environment. The catheter balloon should be tested before catheterization and every catheter

should be generously lubricated before insertion, which are key to prevent majority of catheter related complications and morbidity.

References:

1. Ha US, Cho YH. Catheter-associated urinary tract infections: new aspects of novel urinary catheters. *Int J Antimicrob Agents* 2006;28:485-90.
2. Maki DG, Tambyah PA. Engineering out the risk of infection with urinary catheters. *Emerg Infect Dis.* 2001;7:16
3. Maki DG, Tambyah PA. Engineering out the risk for infection with urinary catheters. *Emerg Infect Dis* 2001;7(2):342-7.
4. Pratt, R. J., C. M. Pellowe, et al. "epic2: National evidence-based guidelines for preventing healthcare-associated infections in NHS hospitals in England." *J Hosp Infect* 2007;65(Suppl 1): S1-S64.
5. Maki DG, Ringer M, Alvarado CJ. Prospective randomised trial of povidone-iodine, alcohol, and chlorhexidine for prevention of infection associated with central venous and arterial catheters. *Lancet* 1991;338:339-343
6. Lee J, Jang J, Kim B, Kim J, Jeong G & Han H. Identification of *Lactobacillus sakei* and *Lactobacillus curvatus* by multiplex PCR-based restriction enzyme analysis. *J Microbiol Methods* 2004;59: 1-6.
7. Stensballe J, Tvede M, Looms D, et al. Infection risk with nitrofurazone-impregnated urinary catheters in trauma patients: a randomized trial. *Ann Intern Med* 2007;147:285-93
8. Tenke, P., B. Kovacs, et al. "European and Asian guidelines on management and prevention of catheter-associated urinary tract infections." *Int J Antimicrob Agents* 2008;31(Suppl 1): S68-78
9. Jahn P, Preuss M, Kernig A, et al. Types of indwelling urinary catheters for long-term bladder drainage in adults. *Cochrane Database Syst Rev* 2007;(3):CD004997.
10. European and Asian guidelines on management and prevention of catheter-associated urinary tract infections. *Int J Antimicrob Agents* 2008;31(Suppl 1): S68-78.
11. Tissot E, Limat S, Cornette C, Capellier G. Risk factors for catheter-associated bacteriuria in a medical intensive care unit. *Eur J Clin Microbiol Infect Dis.*2001;20:260-2
12. Clarke, S.A., Samuel, M., & Boddy, S.A. Are prophylactic antibiotics necessary with clean intermittent catheterization? A randomized controlled trial. *Journal of Pediatric Surgery* 2005; 40, 568-71..
13. Shah PN, Desai R, Macho B. Management of a knotted infant feeding tube in the urinary bladder. *Internet J Urol.* 2005;2:2.
14. Carlson D, Mowery BD. Standards to prevent complications of urinary catheterization in children: Should and should-knots. *J Soc Pediatr Nurs.* 1997;2:37-41.

Dr. R.C. Brahma¹
MS, FMAS, PGCHM
Dr. Swapan Deka Manindranath²
LLM, Ph.D

Address :

1. Associate Prof. of Surgery
AMCH, Dibrugarh
2. Associate Prof. of Law
Dispur Law College
Guwahati



Consent in Surgical practice: An analysis

ABSTRACT

Whenever patient consults a doctor, a relationship is established between the two which is considered to be commercial in nature. To avoid any future litigation, it is always advisable on the part of the doctor to have a written agreement in the form of consent between him and the patient the moment he performs any diagnostic, therapeutic or surgical procedures. Consent may be implied, expressed or informed consent which may be oral or written. If the doctor performs any procedure without the consent of patient, except in the case of emergency, he may be charged with assault or battery. This paper aims to analyze the legal significance of "Consent" in doctor-patient relationship with special reference to surgical practice.

Key Words : *Doctor-patient relationship; Informed consent; surgical procedures.*

Introduction :

The relationship between a doctor and a patient is considered to be commercial in nature. Such commercial relationship may be contractual or may not be contractual in nature. In absence of a written contract often the doctor is dragged to the courts. Hence, in order to avoid litigations it is advisable for a doctor to have a written agreement between him and his patient. On the other hand, because of a written agreement the doctor is able to defend his case better in the courts. A written agreement between a doctor and a patient is covered by legal aspects provided in the Indian Contract Act, 1872. Consent is an important element to legally enforce an agreement between a doctor and a patient known as the Contract. The legal definition of "Consent" is provided in Section 13 of the Indian Contract Act, 1872 which says that "Two persons are said to consent when they agree upon the same thing in the same person." In other words, there must be consent ad idem to legally recognize the bilateral transaction between the doctor and the patient. The section 11 of the Indian Contract Act also provides that only those persons who are of and above 18 years of age are competent to enter into a contract. It is advisable that consent should be obtained preferably in written format from parents or guardian who is below 18 years of age, so that the validity of the contract is not challengeable. This basic legal concept was first expressed by Justice Cardozo who stated that, "Every human being of adult years and sound mind has the right to determine what should be done with his body; and the surgeon who performs an operation without his patient's consent commits an assault for which he is liable in damages"[1]. This paper aims to

analyze the legal significance of "Consent" in doctor-patient relationship with special reference to surgical practice.

II. Requirement of Consent.

Law recognises the significance of Consent in a doctor-patient relationship to deal with medico-legal cases. If a medical practitioner treats or operates on a patient without consent, such treatment or operation will be deemed to be intentional interference with the patient's body without legal sanction which amounts to assault and a battery for which will be entitled to recover damages [1]. The legal consent obtained by a medical practitioner may be either implied or expressed or informed consent. Expressed or informed consent may be further written or verbal in form.

Implied Consent - The conduct of the greater part of medical practice is on the basis of 'Implied Consent'. Although this is entirely correct it often misleads the medical practitioners to overlook the fact that medical examination is a subject of consent, which is necessary in the appropriate form [1].

Generally, a routine medical examination of a patient does not require a 'formal written consent' because the patient conducts himself in a manner which implies consent. When a patient attends a surgeon's consulting room or outpatient's department, or when he agrees to be admitted to a hospital or nursing home, he thereby implies that he will submit to routine physical examination like inspection, palpation, percussion and auscultation. Express oral consent must be obtained for relatively minor examinations or therapeutic procedures, preferably in the presence of a disinterested third party. For example examinations of private parts notably rectal, vaginal and withdrawing of blood for diagnostic purposes, express consent in the form of oral or written consent is necessary along with presence of female attendant while examining female patient and male attendant while examining male patient. Similarly for more complex diagnostic procedures like endoscopy, radiological contrast studies and surgical procedures under anaesthesia, written consent should be obtained.

Expressed or Informed Consent -

Informed consent is an ongoing process, a two-way or mutual conversation extending over time, between the registered medical practitioner and the patient, that prior to the consent having been given, the medical practitioner has informed the patient of the nature of the proposed procedure or treatment of those risks and alternative treatment or diagnosis that a reasonable patient would consider material to the

decision whether or not to undergo treatment or diagnosis [1]. Legally, an injection becomes an assault on the person by the doctor if not given properly and justifiably so does blood transfusion -its risks or hazards should be explained to the patient or attendant, so that the consent becomes real.

III. Informed Consent in Surgical Practice

In surgical practice, there is a clinical duty on a surgeon to obtain informed consent before the commencement of treatment. Because of the extremity of their clinical need, patients might agree to surgery on the basis of no information at all. Agreement of this kind, however, does not constitute a form of consent which is morally or legally acceptable. Unless such patients have some understanding of what they are agreeing to, their choices may have nothing to do with planning their lives and thus do not count as expressions of autonomy [1]. Every patient undergoing surgery must have a valid consent. Very often it is noticed that common consent is taken for both for surgery and anaesthesia, however legally there should be a separate consent for anaesthesia.

For agreement to count as consent to treatment, patients need to be given appropriate and accurate information about:

- Their condition and the reasons why it warrants surgery;
- What type of surgery is proposed and how it might correct their condition;
- What the proposed surgery entails in practice;
- The anticipated prognosis of the proposed surgery;
- The expected side-effects of the proposed surgery;
- The unexpected hazards of the proposed surgery;
- Any alternative and potential successful treatments for their condition other than the proposed surgery, along with similar information about these;
- The consequences of no treatment at all.

Good professional practice dictates that obtaining informed consent should occur in circumstances which are designed to maximise the chances of patients understanding what is said about their condition and proposed treatment, as well as giving them an opportunity to ask questions and express anxieties. Where possible:

- A quiet venue for discussion should be found.
- Written material in the patient's preferred language should be provided to supplement verbal communication.
- Patients should be given time and help to evaluate their own understanding and to come to their own decision.
- The person obtaining the consent should ideally be the surgeon who will carry out the treatment. It should not be - as is sometimes the case - a junior member of staff who has never conducted such a procedure and thus may not have enough understanding to counsel the patient properly.

Surgeons should always attempt to approximate these conditions, even when they might not be completely achievable.

Good communication skills go hand in hand with properly obtaining informed consent for surgery. It is not good enough just to go through the motion of providing patients with information required for considered choice. Attention must be paid to:

- Whether or not the patient has understood what has been stated;
- Avoiding overtly technical language in descriptions and explanations;
- The provision of translators for patients whose first language is not English;
- Asking patients if they have further questions.

IV. Exceptions to Informed Consent

Consent is must, however, there may be certain situations when the doctor need not take consent from the patient. Such situations are:

(1) When the doctor may conclude that the disclosure of a risk may pose such a serious psychological threat or detriment to the patient as to be medically contraindicated prompting the patient to forego needed therapy. Such conclusions are based on the discretion of the doctor and are known as "Therapeutic Privilege" or "Professional Discretion". Under such circumstances, the doctor may make the revelations to the next of kin of the patient or to the family physician.

(2) This privilege also applies when a patient is usually sensitive, anxious or emotional. However, a general policy of not disclosing information because of the presumed hypersensitivity of patient is not an acceptable basis for this privilege.

When the physician's use of 'therapeutic privilege' is challenged, it must be determined whether the physician followed sound medical judgment in withholding information.

V. No consent in Emergency cases

Besides the use of 'Professional Privilege', a doctor need not take consent in case of emergency. A case of emergency may arise in the following situations:

(1) No duty to inform arises in an emergency in which the patient is unconscious or otherwise incapable of giving valid consent and harm of failure to treat is imminent and outweighs any harm threatened by the proposed treatment (Article 7 of the Convention of Human Rights and Biomedicine, 1997 held at 4th April at Oviedo, Spain).

(2) Duty not to inform may also arise when the relative/guardian is/are not available or there is no time to contact them; and

(3) Duty not to inform also arise when there is urgency of situation to save the life or avoid further damage (Article 8 of the Convention of Human Rights and Biomedicine, 1997). In these circumstances, law presumes that consent has been given in 'Good faith'. Doctor is immune to penal proceedings for 'damages', 'assault' or 'negligence' since he is protected by Section 92 of the Indian Penal Code.

This exception shall not extend to:

(1) the intentional causing/attempting to cause death;

(2) doing of anything likely to cause death or for any purpose other than preventing of death or of grievous hurt or curing of any grievous disease or infirmity."

In the case of *Dr T.T.Thomas v. Elisa*, the doctor was held liable for not performing an emergency operation and the patient died of peritonitis [1]. In this case patient was admitted to the particular hospital with severe abdominal pain and was diagnosed to be suffering from acute appendicitis. The operation was not performed on that day and on subsequent day patient expired. The plaintiff's case was that had the operation been performed on that day of admission, the patient's life most probably would have been saved. The defendant surgeon took the plea of refusal by the patient to give his consent to the operation. The argument was not accepted as there was no mention in the case sheet of the patient that consent was sought and the same was refused by the patient. The court held doctor negligent in his conduct in as much as the

patient had passed into a critical stage where the prime importance and the professional duty of a doctor is to save the life of a patient by doing all that is possible. Sometimes a person may have some hesitation, initially to undergo any kind of operation, but when there is only one alternative to safeguard the health and life of the patient the doctor should not evade the responsibility and he becomes answerable for any untoward happening that may take place due to his inaction. It was held that in case of emergency operation the doctor cannot wait for the consent of his patient where the patient is not in a fit state of mind to give consent or to give a conscious answer regarding consent or where the patient is minor.

VI. Right to Refuse Consent:

When a patient or his guardian rejects or refuse a treatment, he should be advised in a discreet, ethical, moral and professional manner about the consequences of not taking treatment. After that it is open to the patient or his guardian whether they want to continue the treatment or not. If not, the same may be noted down in the records of the patients case sheets as "left against medical advice" (LAMA) and normally signature of the legal guardians should be obtained before the patient is discharged.

In normal circumstances if consent is refused, it is an absolute bar for examining or initiating treatment to a patient. If a doctor fails to give correct information regarding the procedure before consent, he may be sued for negligence u/s 304 IPC or punished by the Medical Council of India or the State Medical Council for unethical act or professional misconduct.

If he does not take consent at all, he may be charged with assault u/s 351 IPC trespass of privacy

VII. Age for Consent:

Most confusing aspect of 'consent' among the medical fraternity is the issue of 'age of giving legally valid consent' for medical purposes. There are three schools of thought among medical jurists. According to one school of thought, it is 12 years, for routine medical examination other than operations and other invasive medical procedures (refer to Sections 87 and 88, IPC). Another school of thought considers it as 12 years for all practical purposes irrespective of invasive or non-invasive medical procedures, and third school of thought considers it as 18 years, for operations or invasive medical procedures, and 12 years for routine medical procedures. This confusion is evident among our legislators, when we go through different statutory provisions like organ transplantation, blood donation,

abortion, etc. However, for all practical purposes person with above 18 years with sound and healthy mind may be considered for giving valid consent.

VIII. Competency for giving consent:

'Soundness of mind' and 'maturity of the mind' may be considered as the most important legal ingredient to understand the nature and consequences to which he is going to give consent. According to sec.90 of IPC, consent given under fear, fraud or misrepresentation of facts or by a person who is ignorant of the implications of his consent, or who is under twelve years of age is invalid. Similarly u/s 92 when legal guardians are not available in case of children or minors, teachers, hostel warden, superintendent, Principal or consent from the court of law can be sought on behalf of the patients in case of emergency.

A telephone consent given by the legal guardian of the patient is also valid in case of emergency when the patient is unable to give consent due to one reason or the other, or is a minor, however, one should have a third party listening in as witness. Moreover, it is imperative that the other party be informed that a third party is listening on the line, along with the purpose and identity of that third party and is always advisable to ask for a confirmatory in the form of message or e-mail or some written document for record.

IX. Scope of Consent:

When a patient gives a consent to a surgical procedure or for a specific type of treatment, the performance of that particular procedure or treatment, the legal validity, the scope of consent is limited to whatever contents were expressed to the patient at the time of obtaining the consent: however in exceptional circumstances an extension of the scope of the consent would be permissible. The general rule is that, a doctor commits assault or battery if he exceeds the scope of the consent given by the patient.

In *Ram Bihari Lal v. Dr J.N.Srivastava* case, the surgeon during an operation for appendicectomy found appendix normal but gallbladder inflamed and likely to become gangrenous [1]. The patient was under anaesthesia and abdomen was open, surgeon in good faith did cholecystectomy without taking consent of her husband and patient died later. The lower court did not hold the surgeon liable as it was in the best interest of the patient but the High Court of Madhya Pradesh reversed the judgement.

X. Conclusion:

Surgeons have a legal, as well as moral obligation to obtain consent for treatment based on appropriate levels of information. Failure to do so could result in a legal action of battery or negligence. Also both professionally and legally, it is important for surgeons to understand that a signed consent form is not proof that valid consent has been properly obtained. It is simply a piece of evidence that consent may have been attempted. Even when they have provided their signature, patients can and do deny that appropriate information has been communicated or that the

communication was effective. Surgeons are therefore well advised to make brief notes of what they have said to patients about their proposed treatments, especially information about significant risks. These notes should be placed in the patient's clinical record, moreover video recording can also be made about the conversation and explanation between the patients and doctors regarding the informed consent about the proposed treatment, procedures, expected complications and outcome with prior permission of the patient, so that evidence can be produced in the court or to the competent authorities if there is any litigation.

References:

1. Scholendroff v. Society of New York Hospital. 103 NE 92 cited in Roshan Lall Gupta. *The Medicolegal Aspects of Surgery*. 1st edition, Jaypee Brothers Medical Publishers (P) Ltd. New Delhi, 1924; pp. 16-17.
2. Prof. (Dr.) R. Chaliah, "Consent-Medical And Legal Aspects". Paper presented at Forensic Medicine 2014, Guwahati, Assam. 31st January - 2nd February 2014. Organized by 35th Annual National Conference of Indian Academy of Forensic Medicine.
3. Putul Mahanta. *Modern Textbook of Forensic Medicine & Toxicology*. Jaypee Brothers Medical Publishers (P) Ltd. New Delhi, p. 35-39
4. Justice K Kannan, Dr K Mathiharan. Modi, A *Textbook of Medical Jurisprudence and Toxicology*, 24th Edition, Lexis Nexis Publication, A division of Reed Elsevier India Pvt Ltd, Gurgaon, Haryana, India, pp 76-77.
5. R.C.G. Russel, Norman S. Williams & Christopher J.K. Bulstrode (eds.), *Bailey & Love's Short Practice of Surgery*, 24th ed., International Students Edition, Holder Education, London in Len Doyal, *Surgical ethics*, pp. 251-256.
6. Dr T.T.Thomas v. Elisa. All India Reporter 1987 Ker 52: (1987) (1) ACJ 192. cited in Modi, A *Textbook of Medical Jurisprudence and Toxicology*, 24th Edition, Lexis Nexis Publication, A division of Reed Elsevier India Pvt Ltd, Gurgaon, Haryana, India, pp 76-77.
7. Ram Bihari Lal versus Dr J.N.Srivastava. All India Reporter 1986 MP 150: 1985 ACJ 424: 1985 Jab LJ 259. cited in Roshan Lall Gupta. *The Medicolegal Aspects of Surgery*. 1st edition, Jaypee Brothers Medical Publishers (P) Ltd. New Delhi, pp. 23.

Prof. Rajeev T.P.
Dr. Hrishikesh Bordoloi
Dr. Debanga Sarma
Dr. Sasanka Kumar Barua
Prof. Saumar Jyoti Barua
Dr. Puskal Kumar Bagchi

Address :
Dept. Urology
Gauhati Medical College Hospital
Guwahati - 781032, Assam, India
E-mail : rajeevtpgmch@yahoo.co.in



Impact of stone clearance in patients with urinary stone disease and chronic kidney disease

ABSTRACT

Chronic renal failure (CRF) in calculus kidneys is a common problem in developing countries. Obstruction, pyonephrosis and renal failure are a direct consequence of renal stones. Urologists tend to hesitate to intervene when chronic renal failure occurs. Eighteen patients with 33 functional renal units with urinary stone disease and CKD, without any known medical renal disease were taken up for study. The outcome of surgical intervention was studied by pre-op and post-op GFR values, calculated using the MDRD formula based on serum creatinine values.

The mean age was 44.8 years (± 13.03) and male:female distribution was 16:3 (6:1). Patients were subdivided into 2 groups based on the GFR at presentation; Group 1 CKD stage III had 7 patients while Group 2 CKD IV/V had 11 patients. Out of the 33 renal units operated (3 solitary functioning kidneys), pyelo-nephrolithotomy in 8 (5+3); URSL for 3; Ureterolithotomy in 11 and PCNL in 3 units. Complete clearance was achieved in 29 (87%) and partial clearance in 4 (12%) renal units (non-obstructive residual calculi > 4 mm). Follow up with estimated GFR value was carried out at 3 months after stone clearance. The mean pre-operative GFR was 25.6ml/min (S.D. ± 13.43 ml/min) and the mean post operative GFR at 3 months was 38.5ml/min (S.D. ± 22.97 ml/min). The complication rate was 26%. There was overall significant improvement (P value on paired t test 0.0346) in the post-operative GFR levels (-12.83ml/min) though when calculated group wise, it was only significant for Grp2.

Urolithiasis remains one of the potentially avoidable causes of CKD in many patients. An earnest effort with timely intervention in early CKD stages may salvage the kidney. In higher grades of CKD the surgical decision should rely on minimizing renal injury. Endourological procedure's outcomes rivaled open surgery in selected cases. Early stone clearance and prevention of recurrence with metabolic evaluation and appropriate dietary modification may prevent grade progression.

Key Words : *Chronic kidney disease, Urolithiasis, Renal Stone, ESRD, Chronic Renal Failure*

Introduction :

Chronic kidney disease in calculus kidneys is a common problem in developing countries. Obstructive uropathy as a result of kidney stone disease has been contributing to ever increasing numbers of such patients. Obstruction, pyonephrosis and renal failure are a direct consequence of neglected urinary tract stones. Nephrologists and urologists tend to hesitate to intervene when chronic kidney disease sets in. The diagnosis and

intervention in patients with chronic kidney disease (CKD) is often delayed due to ignorance of the patient, socioeconomic reasons and reliance on unconventional therapy. If prompt radical measures are undertaken in such azotemic patients, the morbidity and dependency on dialysis may be reduced and time to progression to end stage renal disease (ESRD) may be delayed.

The effect of various surgical intervention for stone disease on renal function is an important determinant for selecting the optimal therapy in patients with CKD[1]. This study is to prospectively evaluate the efficacy and outcome of stone clearance on improving the function of renal unit in patients with CKD.

PATIENTS AND METHOD

During the period from January 2013 till December 2014, 18 cases with evidence of elevated creatinine values and urinary stone disease without associated medical renal disease were prospectively evaluated. Ultrasound study and X-Ray KUB (Kidney Urinary Bladder) and Renal function test (RFT) were routinely used for screening and serum creatinine values and Modification of Diet in Renal Disease (MDRD) formula was applied to evaluate the Glomerular Filtration Rate (GFR). Patients were divided into 2 groups based on GFR : Group-1 - CKD stages I-III(i.e. GFR more than 30ml with renal functional compromise); Group 2 - CKD IV/V (i.e GFR less than 30 ml/minute/1.73 m). In case of obstructed and infected systems a preliminary percutaneous nephrostomy or DJ stenting and culture-specific antibiotic treatment carried out. An Intravenous Urogram (IVU) or Non Contrast Computed Tomogram (NCCT) studies in patients with creatinine above 2.5mg/dl were done and stone burden was determined by multiplying the stone length by the width in millimeters squared.

Patient characteristics and stone characteristics were the determining factors for selection of the operative technique with an aim of relieving obstruction and ensuring complete stone clearance. Open surgeries such as pyelolithotomies, nephrolithotomies and ureterolithotomies were performed wherever endourological procedures such as percutaneous nephrolithotomy (PCNL) and Ureteroscopic Lithotripsy (URSL) were deemed not feasible considering the stone bulk, presence of anatomical obstruction, and need for multiple procedures to ensure stone clearance. Auxiliary procedures, including second-look PCNL, ureteroscopy, and extracorporeal shock wave lithotripsy (ESWL) were used to achieve complete stone clearance. Patients were rendered stone free when residual fragments were smaller than 4 mm with or without adjuvant treatments. Nephrology consultation

was obtained for all patients prior to planning of therapy. Postoperative renal function was estimated using serum creatinine and MDRD calculated estimated GFR. Patients with established medical renal diseases, history of previous surgical intervention for stone disease and presenting with acute on chronic renal failure were excluded from the study.

RESULTS

In the period of study of 24 months, 18 patients were recruited in the study, and a total of 33 renal units were studied including 3 patients who had solitary functioning units. Estimated GFR (eGFR) values were calculated online using 4 variable MDRD equation using standardized serum creatinine, age, race, gender at www.MDRD.com.

The male female distribution were 16:3(6:1) and the mean age of patients was 44.8 years (± 13.03) and a range from 20 to 65 years. Group I with CKD stage III had 7 patients while Group II CKD IV & V had 11 patients. During pre-operative management to relieve obstruction and in infected units before PCNL, double J stents were placed in 19 (57%) and per cutaneous nephrostomy drainage was done in 10 (30%). Haemodialysis was carried out in 11 patients pre-operatively. Open surgeries were carried out in 23(69%) units where ureterolithotomies were done in 16 (48%) of ureteric stones and 5 pyelolithotomies and 3 nephrolithotomies either as a solitary form of management or in combinations. PCNL to achieve clearance was done in 3 renal units while URSL was done in 5 renal units. Blood transfusions pre-operatively or operatively were given with a mean value 2.6 units per patient

Complete clearance was achieved in 29(87%) and partial clearance in 4(12%) renal units where non obstructive residual calculi (>4mm) remained. The mean creatinine values pre operatively was 3.79mg/dl (S.D. ± 2.45 mg/dl) and post operative 3.17mg/dl (S.D. ± 3.05 mg/dl). The mean post-operative change in serum creatinine value was 0.62mg/dl. The 'P' value on Paired t test (0.484) is not statistically significant. The mean pre-operative GFR was 25.6ml/min (S.D. ± 13.43 ml/min) and the mean post operative GFR was 38.5ml/min (S.D. ± 22.97 ml/min), the mean GFR improvement was significant (-12.83ml/min) on Paired 't' test ('P' value 0.0346). The significance of change in GFR value is attributable to the application of the MDRD formula.

The group wise change in GFR values for group I: pre-operatively 40ml/min (S.D. ± 5.19) and post-operatively 72.16ml/min(S.D. ± 12.04) and for group II: pre-operatively 16.54ml/min (S.D. ± 7.44) and post-

operatively 37.63ml/min(S.D.±28.42). The 'P' value (0.9751 on paired t test) for change in GFR for group I is not statistically significant while it was statistically significant for group II (0.0231). The creatinine values showed improvement in group II with the mean decrease in 1.1mg/dl while there was insignificant increase in group I post operatively (0.14mg/dl

In the study 3 patients with solitary functional kidneys who underwent intervention, the mean improvement in creatinine and GFR values were 3.95mg/dl and 15.67ml/min. The mean improvement in creatinine value in patients in our series undergoing PCNL was 1.05mg/dl and the mean improvement in GFR was 30ml/min.

The complication rate was 26% on the total number of primary and ancillary procedures. The commonest complication was post-operative fever (7 patients) which were managed conservatively with sensitivity matched antibiotics and symptomatic management. Three patients had surgical site wound infection managed conservatively. Intensive care had to be arranged for 6 post operative patients, 4 of them belonging to group II. Relook PCNL was performed in 1 patient. Cystolithotripsy was performed in 2 patients.

DISCUSSION

The changes in epidemiological trends of urolithiasis and the prevalence of renal failure in the last few decades have led to rise of such cases in underdeveloped countries such as India. Current data suggest 0.2-3.2% of all ESRD cases have stone disease as the primary cause[2]. The etiology of CKD in patients with kidney stone disease is multifactorial and can be attributed to obstruction, urinary tract infection, frequent surgical interventions, and coexisting medical disease[3,4]. Neglected urinary stones constitute as the one of the commonest cause of chronic renal failure and 10-15% of patients with calculous disease ultimately progress to chronic renal failure[5,6].

Gupta et al. justified the need of an aggressive approach to clear stones in patients presenting with calculous nephropathy and azotemia[7]. They also showed that rendering patients stone free with elevated creatinine values benefited their renal function independent of the relief of obstruction.

Open surgical stone removal is rarely performed in today's practice. There are, however, some patients with extremely complex staghorn stones, those with coexistent abnormalities of the collecting system or ureter, and those who have failed minimally invasive approaches who may require this approach.

Eterovi? and associates evaluated 30 patients who underwent pyelolithotomy with DTPA and 131 I

Hippuran renal scans preoperatively and 3 months postoperatively[8]. Effective Renal Plasma Flow(RPF) increased 72% in the treated kidney at 3 months. GFR increased 81% at 3 months postoperatively. Balbay and associates studied 12 patients who underwent nephrolithotomy without pyelolithotomy with DMSA scans and there was a 16% mean decrease in tracer uptake in the operated renal unit at 1 month and 10.8% at 3 months; the latter is not statistically significant[9]. Similar study by Witherow and Wickham on 19 patients with renal insufficiency and creatinine clearance ≥ 20 mL/min, who underwent nephrolithotomy, increased mean creatinine clearance significantly from 12.9 to 25.4 mL/min (mean follow-up of 6.3 years), preventing the need for dialysis[10]. They also described their experience with nephrolithotomy on 29 patients with solitary kidneys. Serum creatinine levels rose in all patients immediately after the operation; however, at a mean follow-up of 26 months, 19 of the 29 patients had return of their creatinine to baseline, 8 experienced a reduction in creatinine, and 2 had a significant increase.

Singh and colleagues performed open surgical removal with nephrolithotomy and pyelolithotomies on 70 patients with renal stones and varying degrees of renal insufficiency of which 63 underwent combination procedure[11]. They measured GFR from Diethylenetriamine pentaacetate (DTPA) scans 6 to 9 months postoperatively and reported mean increases in this parameter. Al-Kohlany and associates assessed renal function with Meraptoacetyl triglycine (MAG3) scans in patients harbouring staghorn stones who were treated with open surgery, including modified Anatomic nephrolithotomy (ANL), extended pyelolithotomy, and combined pyelolithotomy/nephrolithotomy[12]. They found no significant decline in the involved renal unit at a mean of 4.9 months after these procedures; results were not segregated by technique.

In our study open surgeries were carried out in 23(69%) units where ureterolithotomies were done in 16 (48%) and 5 pyelolithotomies and 3 nephrolithotomies either as a solitary form of management or in combinations. The mean post-operative change in serum creatinine value was 0.62mg/dl. The mean pre-operative GFR was 25.6ml/min (S.D.±13.43ml/min) and the mean post-operative GFR was 38.5ml/min (S.D.±22.97ml/min). The mean GFR improvement was 12.9ml/min. Our results matched those of Witherow and Wickham and was better than Balbay and associates, while Eterovi? and associates achieved better improvement in GFR after surgery.

Endourological procedures have long been debated as a better modality for managing obstructing stones with renal dysfunction. PCNL and other endoscopic procedures such as URSL due to their low renal damaging potential, possibly minimizes the loss of renal.

Bilen et al reported the results of 185 patients with a preoperative GFR of 60 mL/min/1.73 m²[13]. Treatment of stone disease by PNL improved the GFR and CKD stage, especially in patients with end-stage renal disease. Canes et al reported that PCNL in solitary kidney was safe and resulted in renal function preservation for upto 1 year of follow-up[14]. Kukreja and associates retrospectively studied the outcome of PCNL in 87 renal units with various degrees of renal insufficiency[15]. Overall, 67.9% of patients had improvement or stabilization of their renal function at an average follow-up of 2.2 years. Bilen et al reported the results of 185 patients with a preoperative GFR of 60 mL/min/1.73m². The mean improvement in creatinine value in our series undergoing PCNL was 1.05mg/dl and the mean improvement in GFR was 30ml/min. The improvement in renal function may be due to relief of the underlying obstruction

There is limited information on the impact of intervention in patients with solitary kidney with renal insufficiency. Liou and Stroom reported no significant long-term postoperative change in serum creatinine or estimated GFR in 18 patients with solitary kidney at a mean follow-up of 68 months[16]. They did demonstrate a significant positive correlation between pretreatment serum creatinine with the subsequent increase in GFR for patients with renal insufficiency. In our study 3 patients with solitary functional kidneys underwent intervention and the mean improvement in creatinine and GFR values were 3.95mg/dl and 15.67ml/min.

Gupta et al. showed that rendering patients stone free with elevated creatinine values benefited their renal function independent of the relief of obstruction. They justified the need of an aggressive approach to clear stones in patients presenting with calculous nephropathy and CKD and suggested that the progression to chronic kidney disease due to nephrolithiasis may be mitigated. Singh and colleagues reported 27% increase in GFR in those with mild CRI (serum creatinine <2.0 mg/dL), 14% in those with moderate CRI (serum creatinine 2.0 to 4.0 mg/dL), and 11% in those with severe CRI (serum creatinine > 4.0 mg/dL)[11]. Kukreja and associates reported that patients with more severe CKD were at risk for developing end-stage renal disease, all five patients with serum creatinine > 6 mg/dL progressed to ESRD[15].

There was significant reductions in renal function in 25.6% patients with a serum creatinine of 2.0 to 2.9 mg/dL, and 43.5% with a serum creatinine of 3.0 to 5.9 mg/dL. In our study group I i.e. CKD III the GFR values were pre-operatively 40ml/min (S.D.±5.19) and post-operatively 72.16ml/min(S.D.±12.04) with a mean change of 32.17ml which was significant. In the other group II with CKD IV/V the GFR values were pre-operatively 16.54ml/min (S.D.±7.44) and post-operatively 37.63ml/min(S.D.±28.42) with a mean change of 21.09ml/min which too was significant. The group with severe form of CKD showed improvement in follow up, though two patients on longer duration of follow up eventually progressed to ESRD.

Canes and associates used a prospective database with retrospective chart and concluded that 37% of patients improved their CKD class; 56% remained stable, and only 7% had worsened 1 year after intervention[14]. The results in our study are similar with 11% progressing to ESRD. Bilen and colleagues noted, that renal function improvement was more likely to be found in patients who had a higher CKD stage than in patients with lower stage disease. In our study the group with higher CKD changes showed better improvement in GFR in the early post operative period.

In our study GFR was calculated using serum creatinine pre and postoperatively. In CKD, it is difficult to estimate differential GFR as ⁹⁹Tc DTPA renal scan is unreliable and MAG-3 is not widely available. In the guidelines for the diagnosis and classification of CKD, the National Kidney Foundation has recommended the use of the MDRD equation to predict the renal function and diagnose CKD[17]. The MDRD equation estimates the GFR value by taking into account the serum creatinine, age, sex, race, and body size and is more accurate than the serum creatinine level in assessing the renal function.

The study had several limitations, including the modest sample size, intermediate-term follow-up, the absence of stone composition and, perhaps most importantly, the absence of a control group. Without a control group, it is impossible to determine the true effect of surgical intervention on the natural history of renal function in patients with CKD. It would also be important to determine whether stone composition (eg, struvite vs calcareous) or morphology (staghorn vs nonstaghorn) is associated with changes in renal function. Although this study provides support that intervention is essential in patients with pre-existing CKD, additional studies are needed to evaluate and compare amongst various forms of interventions.

CONCLUSION

Urolithiasis remains one of the potentially avoidable causes of CKD in many patients. CKD due to urolithiasis is a permanent and progressive entity and its assumed end point is ESRD. An earnest effort with timely intervention in early CKD stages (I to III) may salvage the kidney. The intent to achieve stone free status is foremost and dedicated follow up of such patients with adequate control of infection is necessary. Endourological procedure's outcomes rivaled open surgery in selected cases. Prevention of recurrence with

appropriate metabolic evaluation and dietary modification can prevent grade progression.

Need of aggressive management cannot be denied but higher grade of CKD (stages - III&IV) warrants cautious management. Sincere efforts to relieve obstruction and control infection should be made to arrest progression or delay ESRD. In higher grades of CKD the surgical decision should rely on minimizing renal injury. Despite all efforts in the event of progression to ESRD, renal replacement therapy is the only alternative.

REFERENCES

- [1] Ozden E, Mercimek MN, Bostanci Y, Yakupoglu YK, Sirtbas A, Sarikaya S. Long-term Outcomes of Percutaneous Nephrolithotomy in Patients With Chronic Kidney Disease: A Single-center Experience. *Urology* 2012;79: 990-5.
- [2] Alexander RT, Hemmelgarn BR, Wiebe N, Bello A, Morgan C, Samuel S, Klarenbach SW, Curhan GC, Tonelli M. Kidney stones and kidney function loss: a cohort study; *BMJ* 2012;345:e5287 doi: 10.1136/bmj.e5287.
- [3] Ludwig M, Utsch B, Monnens LA. Recent advances in understanding the clinical and genetic heterogeneity of Dent's disease. *Nephrol Dial Transplant* 2006;21:2708-17.
- [4] Tosetto E, Ghiggeri GM, Emma F, Barbano G, Carrea A, Vezzoli G, et al. Phenotypic and genetic heterogeneity in Dent's disease-the results of an Italian collaborative study. *Nephrol Dial Transplant* 2006;21:2452-63.
- [5] Gupta NP, Kochar SG, Wadhwa SN, Singh SM. Management of patients renal and ureteric calculi presenting with chronic renal insufficiency. *BJU* 1985; 57:130.
- [6] Bhaduria RPS, Ahlawat R, Sriwastava A, Vijay RK, Banerjee G, Bhandari M. Functional outcome and place of endourological management of calculous disease in patients with chronic renal failure. *Ind J Surg* 1993; 55: 619.
- [7] Gupta M, Bolton DM, Gupta PN, Stoller ML. Improved renal function following aggressive treatment of urolithiasis and concurrent mild to moderate renal insufficiency. *J Urol* 1994; 152: 1086-90.
- [8] Eterovi? D, Jureti?-Kusci? L, Capkun V, Duji? Z. Pyelolithotomy improves while extracorporeal lithotripsy impairs kidney function. *J Urol* 1999;161:39-44.
- [9] Balbay MD, Varo?lu E, Devrim H, et al. Quantitative evaluation of renal parenchymal mass with 99mtechnetium dimercapto-succinic acid scintigraphy after nephrolithotomy. *J Urol* 1997;157:1226-8.
- [10] Witherow RO'N, Wickham JEA. Nephrostolithotomy in chronic renal failure: Saved from dialysis! *BJU* 1980; 52:419-21.
- [11] Singh I, Gupta NP, Hemal AK, et al. Efficacy and outcome of surgical intervention in patients with nephrolithiasis and chronic renal failure. *Int Urol Nephrol* 2001;33:293-8.
- [12] Al-Kohlany KM, Shokeir AA, Mosbah A, et al. Treatment of complete staghorn stones: a prospective randomized comparison of open surgery versus percutaneous nephrolithotomy. *J Urol* 2005;173:469-73.
- [13] Bilen CY, Inci K, Kocak B, et al. Impact of percutaneous nephrolithotomy on estimated glomerular filtration rate in patients with chronic kidney disease. *J Endourol* 2008;22:895-900.
- [14] Canes D, Hegarty NJ, Kamoi K, et al. Functional outcomes following percutaneous surgery in the solitary kidney. *J Urol* 2009;181:154-60.
- [15] Kukreja R, Desai M, Patel SH, Desai MR. Nephrolithiasis associated with renal insufficiency: factors predicting outcome. *J Endourol* 2003;17:875-9.
- [16] Liou LS, Streem SB. Long-term renal functional effects of shock wave lithotripsy, percutaneous nephrolithotomy and combination therapy: a comparative study of patients with solitary kidney. *J Urol* 2001;166:36.
- [17] Eknoyan G, Levin NW. K/DOQI. clinical practice guidelines for chronic kidney disease: evaluation, classification and stratification:foreward. *Am J Kidney Dis* 2002;39:S14.

Dr. Mauchumi Baruah
Dr. H.K.Dutta
Sri D. Borbora

Dr. H. K. Dutta
Dept. of Pediatric Surgery
Assam Medical College & Hospital,
Dibrugarh,
Assam, India. Pin: 786002.
E mail: hemontdut@gmail.com



Maternal nutrition and congenital malformation

ABSTRACT

Aims : Maternal iodine deficiency causes wide spectrum of disorders and congenital malformations (CM) in the fetus. Earlier studies have shown higher prevalence of endemic goitre in Dibrugarh district of Assam. The present study is aimed to find out the iodine status among pregnant women and its effect on the fetus.

Methods : Estimation of urinary iodine (UI) level in casual urine samples was done in each trimester in 180 pregnant women (age 18-35 years). Body mass index (BMI) was also assessed in all of them. Detailed information was obtained regarding food habits, source of drinking water, type of salt consumed and obstetrical history. Urine samples from 160 age-matched non-pregnant women from the same locality were taken as controls.

Results : Mean and median UI values were normal in all pregnant women. Significantly higher values were noted during the second trimester and among the older women. Goitre was recorded in 23 women, mostly among multigravida and younger women. There was 1 stillborn and 12 preterm babies. 16 babies had CMs. In the control group 2 women had low UI and high TSH values requiring treatment. 23.3% of the mothers had low BMI and 4 of the total 7 major CMs were noted in this group.

Conclusion : Normal UI recorded in the study may be because of universal consumption of iodized salt. Factors other than iodine deficiency may be responsible for higher incidence of CMs noted in this study. The prevalence of major malformations among the underweight mothers were significantly high.

Key Words : congenital malformations; iodine nutrition; iodine deficiency, BMI.

Introduction :

Disorders resulting from severe iodine deficiency affect more than 400 million people in Asia alone [1]. In India, the classical belt of iodine deficiency disorders (IDD) includes five north eastern states of India including Assam [2]. An earlier study recorded a high prevalence of endemic goitre among the population of Dibrugarh district in upper Assam [2]. High prevalence of congenital malformations was also recorded in certain communities of the district [3]. The present study was conducted to assess the iodine nutritional status and BMI among a section of pregnant women in Dibrugarh and to note any malformations among the offsprings.

Materials & methods:

180 pregnant women were included in the study spanning 2 years. Women who had missed abortion during the 1st or early 2nd trimester were excluded from the study. History obtained regarding food habit, type of salt consumed, source of drinking water and past obstetrical history. Clinical evaluation of women done to grade the goiter if present. Urine samples from 160 age-matched women were collected as controls. Urine iodine estimation was done using the Sandell-Kolthoff formula. 50 ml of random urine sample was collected to which 2-3 drops of Toluene added to prevent bacterial growth. Stock solutions (1 µg iodine/ml) with working standards of 20, 50, 100, 200 and 300 were prepared. A pooled urine sample was prepared for internal quality control assessment. The mean and standard deviation of this sample was calculated and analyzed with every batch of test samples. The 95% confidence interval (CI) was then calculated and used as the operating control range. A standard curve was constructed by plotting iodine concentration of each standard on the abscissa against its optical density on the ordinate. Student's t-test was employed to analyze the observations. Maternal BMI was assessed according to WHO BMI cut-off points and categorized as low (<18.5 kg/m²), recommended (18.5-22.9), and overweight (> 23 kg/m²).

Results:

The source of drinking water of the studied population was hand pump and tap water. All women used iodinated salt. Mean and median UI values were within normal limits in all women. No significant difference of UI levels was noted between the primi and multigravida women and the younger and older women during the 1st and 3rd trimesters. However, significantly higher values of UI were noted during the second trimester and among the older women (26-35 years) (p< 0.05) (Table 1). The UI levels were also significantly higher in the test population than the control group (p<0.001) (Table 2). Goitre was recorded in 14.1% of the women, mostly among the multigravida and younger women. One baby was stillborn. 12 babies were born preterm. Malformations were noted in 16 babies. In the control group 2 women had low UI and high TSH values requiring treatment. 23.3% of the mothers had low BMI and 11.9% of them had babies with CMs. 72.8% of the mothers had recommended BMI and 9.2% of them had CMs [OR= 1.34(0.44-4.05); p=0.551] (Table 3).

Table 1: UI levels in various age groups

Time of gestation	18 – 25 years		26 – 35 years		Significance
	Mean UI (µgm/l)	S.D.	Mean UI (µgm/l)	S.D.	
1st trimester	220	± 75.91	225	± 79.11	(p>0.05)
2 nd trimester	224.93	± 85.70	252.04	± 64.51	(p<0.05)
3 rd trimester	242.42	± 70.58	244.73	± 77.93	(p>0.05)

Table 2: UI levels among control & studied population

Group	Gestation	Mean UI (µg/l)	SD	Significance
Controls	--	117.94	± 45.26	--
Primigravida	1 st Trimester	206.66	± 78.65	P<0.001 (HS)
	2 nd Trimester	223.11	± 83.00	P<0.001 (HS)
	3 rd Trimester	247.91	± 68.12	P<0.001 (HS)
Multigravida	1 st Trimester	228.24	± 75.96	P<0.001 (HS)
	2 nd Trimester	254.20	± 65.04	P<0.001 (HS)
	3 rd Trimester	231.33	± 83.76	P<0.001 (HS)

HS - Highly significant

Discussion:

One of the most important target groups to the effects of iodine deficiency from a public health point of view is pregnant mothers [4]. Pregnancy affects virtually all aspects of thyroid hormone function. The main changes in thyroid function associated with pregnancy are due to an increase in hormone requirements that begin in the first trimester of gestation. This increase can only be met by a proportional increase in hormone production, something that depends directly upon the availability of iodine. When dietary iodine is lacking, an adequate physiological adaptation is difficult to achieve and is progressively replaced by pathological alterations that occur in parallel with the degree and duration of iodine deprivation. Iodine deficiency has an early effect on neuroblast multiplication [5]. Lack of thyroid hormones result in amenorrhea, menorrhagia and infertility, frequent miscarriage, still births and congenital malformations.

Assam falls in the sub-Himalayan endemic zone of IDD. Although theoretically entirely preventable, IDD still prevail in the world because of various socio-economical, cultural, and political limitations to adequate programs of iodine supplementation. Prevention of iodine deficiency in Western countries is most efficiently achieved by programs of salt iodization

at the level of one part of iodide to 10,000-50,000 parts salt, depending on the degree of the deficiency and on salt intake. The present study shows that prevalence of iodine deficiency has decreased significantly among the people who had high prevalence of deficiency few decades back. This may be because of universal use of iodized salt. Currently, 68% of households from areas of the world with previous iodine deficiency have access to iodized salt [6]. A study on 35,223 school children in 28 countries has shown that many previously iodine deficient parts of the world now have median urinary iodine concentrations well above 300 µg/L, which is excessive and carries the risk of adverse health consequences [7].

However, iodised salt is not an ideal means of delivering iodine during pregnancy, because of the need to limit salt intake during this period. Injection of iodized oil given prior to pregnancy have shown to prevent occurrence of neurological syndrome of endemic cretinism in infants [8]. Multivitamin tablets containing iodine has been another method of supplementing dietary iodine [9].

As 90% of the ingested iodine is excreted in the urine, the benchmark method for determining the state of iodine nutrition has been the measurement of excretion of iodine in the urine. One study on iodine nutritional status of pregnant women during 2nd and 3rd trimesters in a rural Indian population found that maternal UIC had limited influence on offspring developmental outcomes [10].

Studies have shown that greater the pre gestational BMI in mother, the higher the risk for CM in their offspring [11]. It was also observed that obese and overweight mothers have significantly increased risk of neural tube defects (NTD) and cardiovascular defects in the babies [12]. However, studies are sparse on risk of CMs among women of less than recommended BMI.

One such study reports that risk of CM was significantly high among the maternal underweight (BMI <18.5 kg/m²) as well as in obese group (BMI >30 kg/m²) compared with mothers who had recommended BMI. Maternal obesity was associated with significantly increased risk of ventricular septal defect (aOR=1.56, P=0.04), cleft lip (aOR=3.71, P=0.04) and eye anomalies (aOR=11.36, P=0.003). Maternal underweight was associated with significantly increased risks of atrial septal defect (aOR=2.86, P=0.02), genital anomalies (aOR=6.30, P=0.009) and hypospadias (aOR=8.77, P=0.02). In the present series, 4 babies born to mothers with BMI <18.5 kg/m² had CMs, 1 had hypospadias, another had atrial septal defect, the 3rd child had cystic hygroma in neck and the 4th had supernumerary fingers. The stillborn baby had myelocoele with bilateral telepes. Watkins et al, after excluding diabetic mothers and other confounders found that compared with average weight women (BMI 19.9-22.9), underweight women (BMI <16.5) were less likely to have a child with major isolated heart defects (OR=0.64, 95% CI 0.43-0.97) [13]. Moreover, periconceptional multivitamin use was reported to be associated with a reduced OR for isolated heart defects among average-weight women (OR = 0.61, 95% CI = 0.36-0.99) and underweight women but not among overweight or obese women (OR=1.69, 95% CI = 0.69-3.84) [14].

The present study found high prevalence (9.4%) of CMs among the studied population. Although prevalence of CMs among underweight mothers and mother with recommended BMI were comparable (OR= 1.34; p=0.5510), the prevalence of major malformations among the underweight mothers was significantly high (OR=6.6; p=0.03). Adjustment for confounding factors (e.g. maternal diabetes mellitus and age) did not change the odds ratios. None of the mothers in the overweight category had babies with any malformations.

References:

1. Hetzel BS. Iodine deficiency disorders (IDD) and their eradication. *The Lancet* 1983;322(8359):1126-9.
2. Epidemiological survey of Endemic goiter and Endemic cretinism. An ICMR Task Force Study. Indian Council of Medical Research 1989, New Delhi..
3. Dutta HK, Bhattacharyya NC, Sarma JN, Kusre G. Congenital malformations in Assam. *J Indian Assoc Pediatr Surg* 2010;15:54-6.
4. Delange F. The disorders induced by iodine deficiency. *Thyroid* 1994;4(1):107-28.

5. Hetzel BS, Mano MT. A review of experimental studies of iodine deficiency during fetal development. *The Journal of Nutrition* 1989;119(2):145-51.
6. Delange F, Benoist BD, Pretell E, Dunn JT. Iodine deficiency in the World: where do we stand at the turn of the Century? *Thyroid* 2001;11(5):437-47.
7. Buttfield IH and Hetzel BS. Endemic goiter in eastern New Guinea with special reference to the use of iodized oil in prophylaxis and treatment. *Bulletin World Health Organization* 1967;36:243-62.
8. Glinner D. The importance of iodine nutrition during pregnancy. *Public Health Nutrition*. 2007;10(12A):1542-6.
9. Lean MIFA, Lean MEJ, Yajnik CS, Bhat DS, Joshi SM, Raut DA et al. Iodine status during pregnancy in India and related neonatal and infant outcomes. *Public Health Nutrition* 2013;1-10. DOI: <http://dx.doi.org/10.1017/S13001201>.
10. Martínez FML, Frías JP, Bermejo E, Rodríguez PE, Prieto L and Frías JL. Pre-gestational maternal body mass index predicts an increased risk of congenital malformations in infants of mothers with gestational diabetes. *Diabetic Med* . 2005;22(6): 775-81. DOI: 10.1111/j.1464-5491.2005.01492.x
11. Stothard KJ, Tennant PWG, Bell R, Rankin J, Maternal Overweight and Obesity and the Risk of Congenital Anomalies: A Systematic Review and Meta-analysis. *JAMA*. 2009;301(6):636-50. doi:10.1001/jama.2009.113.
12. Watkins ML, Botto LD. Maternal prepregnancy weight and congenital heart defect in the offspring. *Epidemiol* 2001;12:439-46.
13. Rankin J, Tennant PWG , Stothard KJ, Bythell M, Summerbell CD, Bell R. Maternal body mass index and congenital anomaly risk:a cohort study. *Int J of Obesity* 2010;34:1371-80. doi:10.1038/ijo.2010.66.

Case Report

Dr. Nirmal Kumar Agarwal

Address for Correspondence:
Dr. Nirmal Kumar Agarwal, MS, FIAGES
Associate Professor of Surgery,
Tezpur Medical College
Tezpur -784153, Assam.
Mobile: 98664097914
Email: nksurgeon@gmail.com



Chronic Umbilical Sinus in an adult as a consequence of urachal remnant : A case report

ABSTRACT

Urachal Sinus is one of a spectrum of urachal abnormalities most commonly found in children. They are rarely seen in adult because the urachus is normally obliterated in early infancy.

We describe a 22 years old female patient who was suffering from recurrent infection and discharge from umbilicus for last 1 ½ yrs. Investigation showed a fibrous tract from umbilicus to Urinary bladder, which was confirmed on magnetic resonance scan. She was treated with surgical excision of the tract from umbilicus to bladder. Histology of the excised specimen showed chronic inflammation with no evidence of malignancy. Post operative recovery was uneventful.

Key Words : *Urachus; Urachal remnant; Urachal Sinus.*

Introduction :

Urachal diseases as a result of incomplete obliteration of urachus are mostly seen in children than adults due to urachal obliteration in early infancy. The urachus or median umbilical ligament is a fibrous cord resulting from involution of the allantoic canal. It extends from the dome of bladder to the posterior umbilicus. A partial or complete failure to obliterate after 5th month of gestation can result in urachal abnormalities. The condition is usually discovered in children but a late presentation during adulthood is always possible. An urachal cyst (UC) with infection being the usual mode of presentation in adults. Urachal Sinus(US) is a rare presentation in adult. Since the first description of urachal abnormality by Cabriolus in 1550, few cases have been reported in literature. We describe a case of Urachal Sinus presenting with tender infraumbilical induration, recurrent purulent discharge and infection in a previously healthy female.

Case Report :

A 22 years old local female presented at SOPD with history of recurrent purulent umbilical discharge associated with occasional lower abdominal pain and mild fever for 18 months. She was treated with multiple courses of broad spectrum antibiotics without any improvement. Her general examination was normal. Abdominal examination revealed somewhat inflamed umbilicus with little sero-purulent discharge and a cord like structure felt from the umbilicus towards symphysis pubis for some distance. A working diagnosis of omphalitis or patent urachus was made. Abdominal ultrasound scan showed a fibrous tract in midline tissue from umbilicus (Fig-1). An MRI scan confirmed the diagnosis of Urachal Sinus communicating proximally with the umbilicus (Fig-2).

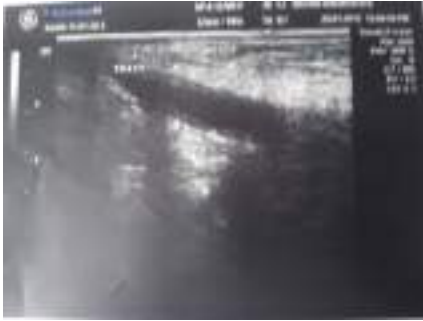

Fig-1 : Ultrasonography showing sinus tract in the extraperitoneal plane

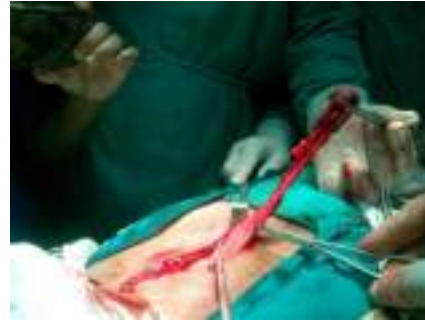

Fig-4 : Completed dissection of the tract upto dome urinary bladder

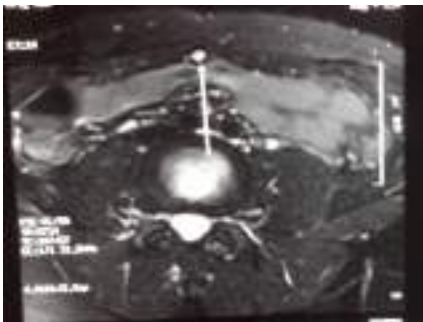


Fig-2 : MRI showing sinus tract between umbilicus and urinary bladder

Possibly because the patient had received antibiotics many times prior to her presentation, she did not show general and local signs of inflammation. she was worked up for surgery. Her haematological examinations were normal. Urinalysis was normal and non-bacteriuric. During surgery, no communication was noted between the bladder and the sinus tract. Complete excision of the sinus tract from umbilicus to dome of the urinary bladder was done with bladder repair using vicryl 2.0 (Fig. 3 & 4). Histo-pathological examination of the tract showed evidence of chronic inflammation with no evidence of malignancy. Recovery was uneventful.

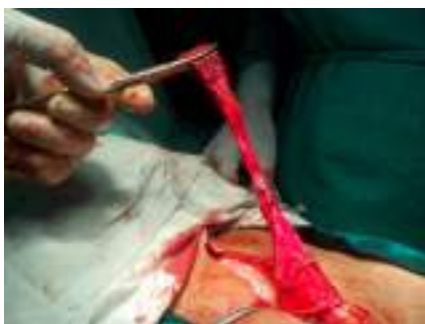

Fig-3 : Dissection of sinus tract through longitudinal of infraumbilical incision

Discussion :

The Urachus is normally embryonic remnant of the dome of primitive bladder which exists as a fibrous cord extending from the dome of the bladder to the umbilicus. At the end of development the Urachus lies between the transversalis fascia and peritoneum in the potential midline space (space of Retzius). Histologically it is composed of three layers - an innermost layer of modified transitional epithelium similar to urothelium, the middle layer of fibro connective tissue and outermost layer of smooth muscle continuous with the detrusor [1,2]. The urachal abnormalities present as, patent urachus, cyst, sinus, and vesicourachal diverticulosis. In Patent Urachus the entire tubular urachus fails to close and urine drains through the urachus. Urachal cyst occurs when both ends of the canal close leaving a cyst like structure within its length. An urachal Sinus drains proximally into the umbilicus, as in this present case. In vesicourachal diverticulosis the distal communication to the bladder persists. Urinary complaints are often reported with this type.

The incidence of urachus sinus(US) in adult is unknown but it is rare. It is more common in men than in women [3]. The commonest mode of presentation of urachal abnormalities in adult is with infection [4,5]. The route of infection is haematogeneous, lymphatic, direct or ascending from the bladder. The commonly cultured microorganism from the infected sinus include Esch. Coli., Enterococcus faecium, klebsiella pneumonie, proteus, streptococcus viridans, fusobacterium and bacteroides sp. The clinical signs and symptoms are non-specific, US are largely asymptomatic until infection supervenes. They present with symptom like some erythema around umbilicus, tendernes below umbilicus, umbilical discharge and sepsis. They cause annoying discharge which may be serous or seropurulent as seen in our patient with little systemic symptom.

Ultrasound can help to make diagnosis in large number of cases and a sinus tract can be seen in subcutaneous plane in the midline from umbilicus. MRI should be done to confirm the diagnosis and define relationship to surrounding structure. US can be complicated by abscess formation, rupture into the peritoneal cavity leading to peritonitis, other reported complication include uracho-colonic fistula, stone formation and neoplastic transformation [6,7]. The risks of urachal malignancy in adult is high and prognosis is poor than that of primary bladder adenocarcinoma [8,9]. Although histologically the innermost layer of the urachus is mainly transitional cell, adenocarcinoma is the predominant histological type due to metaplasia occurring from chronic inflammation [8]. The prognosis is poor as urachal abnormalities are observed rarely in adult and moreover, the urachus is located in a clinically silent area, extraperitoneally in the space of Retzius. As a result, symptoms and signs of inflammation as well as tumours are non-specific and delayed [10].

The treatment of choice for urachal sinus is complete excision. For acutely infected cases particularly abscess formation, a 2 stage procedure involving initial incision and drainage, followed by

later excision of the urachal remnant [5]. Traditional surgical excision of an urachal remnant involves a transverse or midline infra-umbilical incision. The laparoscopic approach for resection of the urachus was first introduced by Trondsen et al [13]. The laparoscopic approach offer many advantages like short duration of hospital stay, early return to normal activity, better cosmetic result etc [11,12,13].

Conclusion :

In summary urachal disease may only present with abdominal pain without obvious periumbilical erythema or exudate in adult. A high index of suspicion is required in order to achieve a diagnosis. A triad of lower midline mass, umbilical discharge and sepsis is suggestive, although ultrasound and MRI confirm the diagnosis.

Treatment of the infected urachal remnant in adult should consist of antibiotic treatment combined with adequate drainage and later followed by complete surgical excision of the remnant including a cuff of bladder. The laparoscopic approach described lately is a safe and effective alternative to open surgery with good long term cosmetic result.

References:-

1. Hammond G, Yglesias L, Davis JE. The urachus, its anatomy and associated fascia. *Anat. Rec* 1941;80:271-4.
2. Begg RC. The urachus : its Anatomy, Histology and Development. *J.Anat* 1930; 64:170-83.
3. Ashley RA, Inman BA, Routh JC, Rohlinger AL, Husmann DA, Kramer SA. Urachal abnormalities : a longitudinal study of urachal remnants in children and adults. *J. Urol* 2007;178: 1615-8.
4. Ash A, Gujral R, Raio C. Infected urachal cyst initially misdiagnosed as an incarcerated umbilicus hernia. *J. Emerg Med* 2012;42:171-3.
5. Yoo KH, Lee SJ, Chang SG. Treatment of infected urachal cysts. *Yonsei Med J* 2006; 47:423-7.
6. Ohgaki M, Higuchi A, Chou H, Takashina K, Kawakami S, Fujita Y, Hegiwara A, Yamagishi H. Acute peritonitis caused by intraperitoneal rupture of an infected urachal cyst : report of a case. *Surg. Today* 2003;33:75- 7.
7. Flanagan DA, Mellinger JD. Urachal-sigmoid fistula in an adult male. *Am Surg* 1998; 64:762-3.
8. Mazzucchelli R, Scarpelli M, Montironi R. Mucinous adenocarcinoma with superficial stromal invasion and villous adenoma of urachal remnants : a case report. *J. Clinpathol* 2003;56: 465-7.
9. Ueno T, Hashimoto H, Yokoyama H, Ito M, Kouda K, Kanamaru H : Urachal abnormalities. ultrasonography and management. *J. Paediatr Surg* 2003;38: 1203-7.
10. Berman SM, Tolia BM, Laor E, Reid RE, Schweizerhof SP, Freed SZ. Urachal remnants in adults. *Urology* 1988;31: 17.
11. Yohannes P, Bruno T, Pathan M, Baltaro R : Laparoscopic radical excision of urachal sinus. *J. Endourol* 2003, 7:475-479.
12. Turial S, Huecksteadt T, Schier F, Fahlenkamp D. Laparoscopic treatment of urachal remnants in children. *J Urol* 2007;177: 1864-6.
13. Okegawa T, Odagane A, Nutahara K, Higashihara E. Laparoscopic management of urachal remnants in adulthood. *Int J Urol*, 2006;13: 1466-9.

Case Report

Dr. Gunabhi Ram Das¹
Dr. Dipak K. Sarma²
Dr. Rocket C. Brahma²
Dr. Anuj K Sarma¹
Dr. David Pegu³
Dr. Nilaksha Bhattacharjee⁴

¹ Assistant Professor
Department of General Surgery, AMCH
² Associate Professor
Department of General Surgery, AMCH
³ Registrar
Department of General Surgery, AMCH
⁴ Post Graduate Trainee
Department of General Surgery, AMCH

Ceroid Granuloma of the Extra Hepatic Biliary System : A rare entity causing obstructive jaundice

ABSTRACT

Ceroid granuloma is a rare cause of obstructive jaundice and closely mimics malignancy of the extra hepatic biliary system. We report a 14 year old female child who was admitted with progressive obstructive jaundice and whose clinical features and radiological investigations were suggestive of biliary tract malignancy. The patient underwent excision of the growth with Roux-en Y hepaticojejunostomy. Histopathological examination found it to be a case of Ceroid Granuloma which has often fallen within the purview of 'malignant masquerades'. It is a rare clinical entity and has been reported to closely mimic malignancy and often impossible to differentiate from malignant neoplasm even with preoperative imaging and cytological studies. Resection with biliary enteric bypass is recommended. The patient recovered following the operation.

Key Words : extra hepatic biliary system; Ceroid Granuloma; obstructive jaundice

Introduction :

Ceroid granuloma is an incidental finding in chronic cholecystitis and choledocholithiasis with an estimated incidence of 2.1 per 100000 population per annum and often mimics malignant neoplasms and with a greater propensity for perforation or fistula formation due to intramural necrosis [1].

Case Report :

A 14 year old female was admitted with complaints of gradual onset dull aching to intermittent episodes of colicky pain in the right upper abdomen, intermittent low grade fever and progressively increasing jaundice for 1 month. She had similar episodes of pain abdomen and intermittent fever for last 6 months associated with anorexia, nausea and flatulent dyspepsia. Her bowel habits and micturition were normal. The patient was malnourished, pale and deeply icteric. There was no cervical or inguinal lymphadenopathy or pedal oedema. She had tenderness over the right hypochondrium, However, there was no muscle guarding, rigidity or ascites or any palpable lump.

Her haemoglobin level was 9.2 gm%, total bilirubin 15.2 mg/dl (direct fraction 10.73 mg/dl) and serum alkaline phosphatase level of 505 IU/l. Her serum albumin level was low at 2.8 g/dl. Ultrasonography (USG) of abdomen showed a distended gall bladder with microcalculi with normal wall thickness and dilated intrahepatic biliary radicles and common bile duct (CBD) with multiple echogenic structures in distal CBD. A repeat USG



2 weeks later revealed a smooth tapering of distal CBD with cutoff and thickened CBD wall (3.6mm). Proximal CBD diameter was 17.6 mm and was suggestive of a type 2 biliary block. There were no calculi visualized in the review USG. An MRCP showed a T1 hypodense and T2 iso to hyperintense soft tissue lesion involving proximal common hepatic duct (CHD) (15.6mm x 11.9 mm) and CBD causing biliary block with gross dilatation of bilobar intrahepatic bile ducts(IHBRs). Cystic duct was seen to drain into the mass lesion. Post contrast study showed relatively homogenous and progressively enhancing soft tissue at the common CHD. Proximal CHD was 19mm, distal CBD 4 mm (normal in caliber), left and right hepatic duct diameters were at 16 mm. MRCP features were suggestive of cholangiocarcinoma or hepatobiliary inflammatory pseudotumour. Preoperative optimization of patient was commenced with injectable antibiotics, inj. vitamin K, diuresis with mannitol and blood transfusions. The abdomen was opened with a right subcostal incision with a left subcostal extension approximately 2.5 cm from the midline and a similar extension superiorly towards the epigastrium in the midline for approximately 2.5 cm. Gall bladder was found to be distended with normal wall thickness. However Calot's triangle was frozen with adhesions. A growth approximately 3cm x 2cm x 2cm was found extending from the Hartmanns pouch engulfing whole of the cystic duct, part of CBD and upto 1 cm distal to confluence at the CHD. Growth was extending into the CBD for

another 1 cm caudally. CHD was around 2 cm in diameter. However, distal CBD was normal in caliber. One periportal node was excised. The patient underwent cholecystectomy with resection of the growth and an end to side Roux-en-Y hepaticojejunostomy with proximal clearance of 1 cm from the growth. A flexible cystoscope was passed into the right and left hepatic ducts and distal CBD to rule out any mass lesions or calculi. The resected specimen along with adjoining lymph node was sent for histopathology examination. Biopsy reports revealed infiltration of gall bladder with dense inflammatory cells consisting mainly of lymphocytes, plasma cells, foamy macrophages and foreign body giant cells around clefts formed by neutral fat.

Section from the growth showed infiltration of dense inflammatory cells with fibrosis. There was no evidence of malignancy and the picture was suggestive of Ceroid Granuloma. The patient received 3 units of blood transfusion and 100 ml of 20 % human albumin. Patient was allowed oral feeding from 7th post operative day. Serum bilirubin level decreased to 6.4 mg/dl on the 14th post-operative day. Serus discharge from the drain site, initially around 200ml decreased gradually and the drain was removed on 21st day. There was also superficial surgical site infection with dehiscence of skin margins and subcutaneous layer, which required secondary closure. The patient was discharged on 24th day of surgery and has been well at 6 months with normal liver function tests.

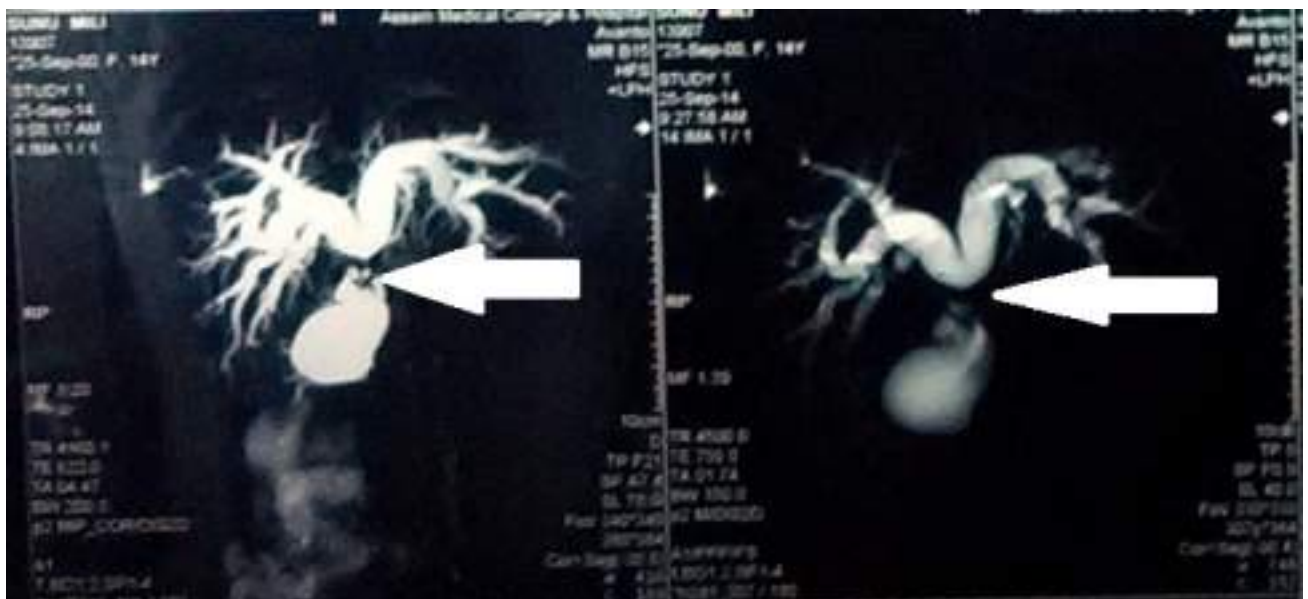

Figure 1: MRCP showing soft tissue lesion (arrow) involving proximal common hepatic duct (CHD) and CBD causing biliary block with gross dilatation of bilobar intrahepatic bile ducts(IHBRs)

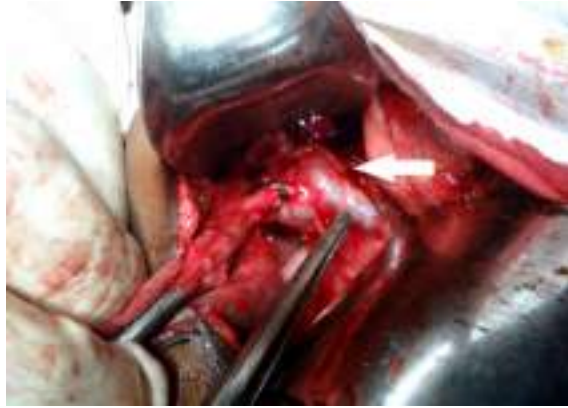

Figure 2: Growth involving CHD, proximal CBD and cystic duct

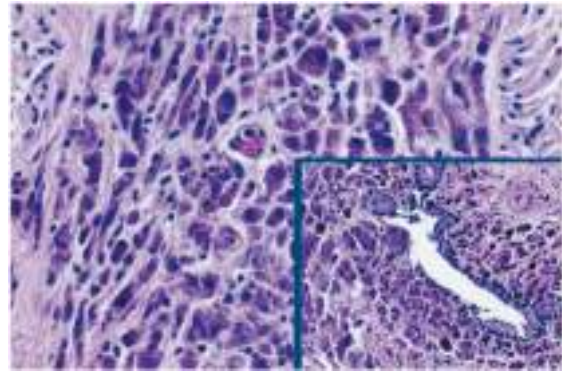


Figure 5 : Photomicrograph of specimen showing dense chronic inflammatory infiltrate around clefts formed by neutral fat

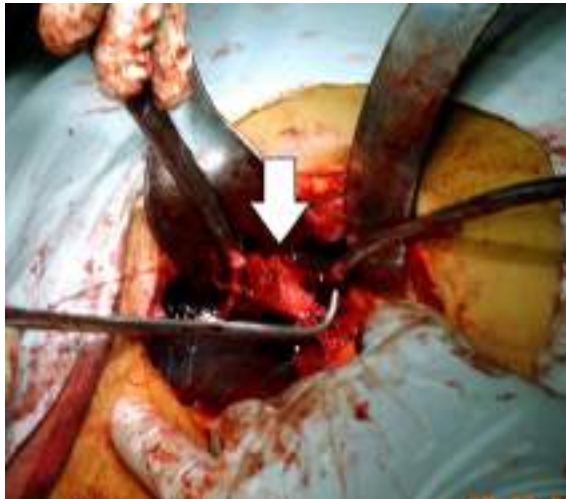

Figure 3 : Growth resected along with CBD and CHD with 1 cm proximal clearance

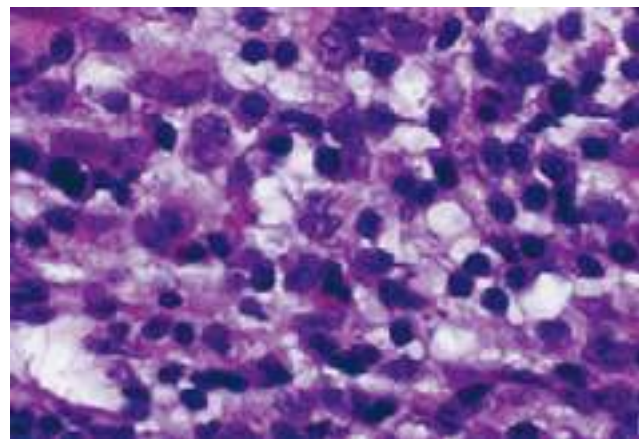


Figure 6 : Photomicrograph (High magnification) showing PAS positive, ceroid laden Granuloma formation

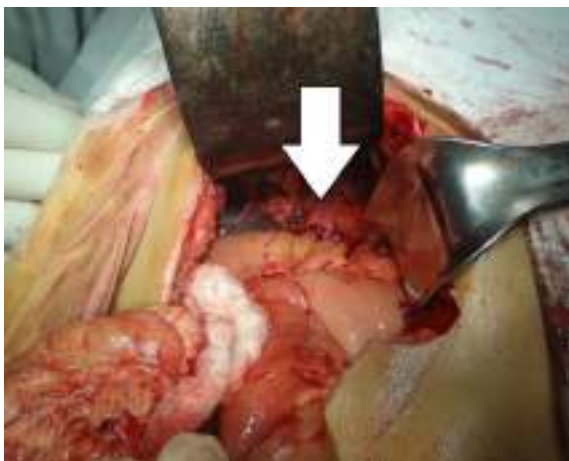

Figure 4 : Excision and Hepaticojejunostomy

Discussion:

Ceroid granuloma of the biliary system is a rare entity with an incidence of 2.1 per 100000 per annum reported in studies [1]. Ceroid granulomas are composed of intramural or mucosal histiocytic infiltration with pale cytoplasm and yellowish brown waxy pigments termed as ceroid. The name ceroid is derived from the Greek word 'keros' indicating the waxy nature of the same. These ceroid pigments are considered to be the early forms of the breakdown pigment Lipofuscin, derived from partial oxidation of lipids and lipoproteins under pathological conditions (cf Lipofuscin which is a naturally occurring wear and tear pigment)[2]. Studies have postulated that bile may serve as a substrate for formation of these ceroid pigments in a background of recurrent cholecystitis and cholangitis associated with breakdown of the Rokitansky-Aschoff sinuses and mucosal ulceration with intramural liberation of bile [3]. These are characterized by acid fastness and diastase resistance

PAS positivity with intense fibrosis and deposition of collagen which may even replace the gallbladder, with progressive dystrophic calcification leading to porcelain gall bladder and/or xanthogranulomatous lesions of the Biliary system.

These lesions are difficult to be differentiated from malignancy even with pre operative imaging and cytology and complete resection of the stricture resulting from the same is recommended [4,5]. Other substrate for ceroidogenesis have been proposed like meconium and vernix, and cases of ceroid granulomas have also been reported in the female genital tract [6,7].

In our case, the onset was insidious with progressive obstructive jaundice with features of cholangitis. MRCP was done for proper delineation of the biliary system in light of the conflicting ultrasound reports initially suggesting cholelithiasis with choledocholithiasis. The MRCP detected a soft tissue lesion at the proximal CHD also involving proximal CBD causing biliary block. There were no calculi which raised the suspicion of a neoplasm of the biliary system causing obstruction to the bile flow. The patient's poor nutritional status along with the findings of MRCP, strongly supported the diagnosis of biliary adenocarcinoma. Reports in the literature have also claimed that it is often very difficult to distinguish between chronic inflammatory conditions and biliary adenocarcinoma, particularly the Scirrhus type [8]. Although MRCP reports suggested a pseudotumour, such pseudotumours are more common in the gallbladder rather than in the biliary tree. Primary benign tumours are also rare in the biliary system as they constitute only 6 percent of all tumours in the biliary system. It is often impossible to distinguish between benign and malignant cause of biliary obstruction and such patients with an obstructing growth must be

considered to have a malignant disease until proved otherwise [8]. Physical findings in the case of biliary tract growth are also vague and non specific, as in our patient, and one must exercise a reasonable amount of caution in first ruling out the more sinister of the conditions before considering the benign conditions.

The term 'malignant masquerade' of the Extra Hepatic Biliary tree was brought into practice in 1984 by Hadjis and colleague in Hammersmith London denoting benign lesions which could not be distinguished from malignant conditions of the biliary system even after extensive pre operative investigations [8]. Several subsequent studies have described such lesions and if the growth was found resectable, the obstructing lesions were removed and a biliary reconstruction and bypass in the form of hepaticojejunostomy was done in majority of the cases. The authors have also concluded that even with modern modalities of investigations, it is impossible to differentiate between the benign and malignant lesions and sometimes even on table frozen section biopsy may be misleading [8].

In our patient, the growth which was firm to hard in consistency with infiltration into the CHD and CBD mimicked a proximal Cholangiocarcinoma and which on on-table assessment was found to be resectable. In light of the existing literature, our decision to achieve an excision with a clear margin and a biliary enteric anastomosis stands validated. However, it was only after proper histopathology examination that malignancy could be ruled out and a diagnosis of a Ceroid Granuloma was made. It is a rare but distinct clinical entity which has often been said to mimic malignancy and has a greater propensity for complications like choledocho-duodenal fistula or perforation.

References :

1. Duarte Z, Guevara U, Vuong PN. Ceroid granulomas of the gallbladder. A clinicopathologic study of nine cases. *Arch Anat Cytol Pathol.* 1994;42(1):5-9.
2. Seehafer SS, Pearce DA. You say lipofuscin, we say ceroid: defining autofluorescent storage material. *Neurobiol Aging.* 2006;27(4):576-88.
3. Takahashi K, Oka K, Hakozaiki H, Kojima M. Ceroid-like histiocytic granuloma of gall-bladder --a previously undescribed lesion--.*Acta Pathol Jpn.* 1976;26(1):25-46.
4. Amazon K, Rywlin AM. Ceroid granulomas of the gallbladder. *Am J Clin Pathol.* 198;73(1):123-7.
5. Krishna RP1, Kumar A, Singh RK, Sikora S, Saxena R, Kapoor VK Xanthogranulomatous inflammatory strictures of extrahepatic biliary tract: presentation and surgical management. *J Gastrointest Surg.* 2008;12(5):836-841. doi: 10.1007/s11605-008-0478-y.
6. Ooi K1, Riley C, Billson V, Ostör AG. Ceroid granulomas in the female genital system.*J Clin Pathol.* 1995;48(11):1057-9.
7. Pikarsky EI, Maly B, Maly A. Ceroid granuloma of the uterine cervix. *Int J Gynecol Pathol.* 2002;21(2):191-3.
8. Koea J1, Holden A, Chau K, McCall J. Differential diagnosis of stenosing lesions at the hepatic hilus. *World J Surg.* 2004;28(5):466-70.

Dr Rocket Chandra Brahma
Dr Sidhartha Sankar Konwar

Address for correspondence:

Dr Rocket Chandra Brahma,
MS, FAIS, FMAS, PGCHM
Associate Professor
Department of Surgery
Assam Medical College and Hospital
Dibrugarh- 786002, Assam
Mobile-9864051733
Email: drcbrhma@yahoo.com

Complications following forgotten DJ urinary stent: A case report

ABSTRACT

Double J stent is most widely used by the urologists for drainage of urine from upper urinary tract to urinary bladder. Though the insertion of DJ stent is to prevent complication following endoscopic and open surgery, the stent itself may cause serious complications like stent migrations, encrustations, sepsis, urinary tract infections and stone formation etc. due to delayed removal of the stent or forgotten stent. We report a classical case of forgotten stent in a twenty seven year old male patient who had undergone ureterolithotomy with DJ stent four years back and had developed stent related complications.

Key Words : *Stent complications; DJ stent; encrustations; forgotten stents; cystolithotomy.*

Introduction :

The double J ureteral stents have become one of the most basic and valuable tools in the urological practice both for endoscopic and open urological surgery. Indwelling ureteral stents provide direct drainage of the upper urinary tract to the bladder without the need for external diversion [1,2]. The indications for insertion of stents into the urinary tract has expanded significantly during the last decade. Stents now are inserted routinely in patients with ureteral obstruction and for prevention of complications following open or endoscopic procedures. However different complications may occur with short or long term use of stents. Initially, very few side effects were reported but later on many publications reported that indwelling ureteral stents can cause lower abdominal pain, dysuria, fever, haematuria, low backache and suprapubic pain [3-5]. Furthermore, indwelling stents can cause major complications like stent migration, encrustation, vesicoureteric reflux, stent fracture, secondary vesical calculus formation or even be forgotten in the patient [6-9].

Case Report :

A 27 years old male patient presented to the surgery outpatient department with history of pain in the suprapubic region, occasional fever, burning micturition for the last 6 months. He took irregular antibiotics and other medications prescribed by the local doctors. He had undergone right side uretero-lithotomy for removal of ureteric stone with DJ stenting about 4 years back at a private hospital, however he lost the medical records except the ultrasonography report. Despite being



advised to come back for check up by the concerned surgeon he ignored the advice. As he was not aware that a DJ stent had been inserted and needed to be removed. His urine analysis revealed plenty of pus cells, serum creatinine, blood urea and other haematological tests were within normal limits. X-ray KUB revealed calculus in the urinary bladder formed on the coil of DJ stent. Ultrasonography revealed mild hydronephrosis of the right kidney, a calculus measuring 33.3mm x 17.4mm was noted in the urinary bladder, and a thin linear hyperechoic area also seen extending from the right renal pelvis upto the urinary bladder which was later on confirmed as DJ stent. Intravenous urography revealed delayed excretion of contrast in the right kidney. The patient was put on broad spectrum antibiotics and posted for suprapubic cystolithotomy under regional anaesthesia. The vesical calculus encrusted around the coiled DJ stent was removed [Figures 1, 2 & 3]. The post operative period was uneventful and the patient was discharged on 7th post operative day. This was a classical case of forgotten DJ stent with encrustation which formed a nidus for secondary vesical calculus formation and other stent associated complications like recurrent urinary tract infections, fever and pain lower abdomen.

Discussion :

The double J stent has been a boon and are being extensively used by the surgeons and urologists practicing both open and endoscopic procedures. The stent allows good urinary drainage from kidney to the urinary bladder and is usually well tolerated by the patients. Despite its extensive use, DJ stents can give rise to several complications which may be manifested as an early and late complication and are most often related to prolonged indwelling times, especially in forgotten or overlooked stents. Early complications may be stent colic, dysuria, haematuria, vesico-ureteric reflux, urinary tract infections, pyelonephritis, fever and flank pain. Late complications includes hydronephrosis, encrustations, stent migration, stent fracture, spontaneous fragmentation, uretero-arterial and uretero-intestinal fistula [9,10]. In a study conducted by Hao P et al, of 2685 cases of DJ stent used for both open and endoscopic procedures, the stents were a safe and useful adjunct if these were removed after 4-6 weeks. In another study, Damiano R et al observed

flank pain (25.3%), encrustation (21.6%), irritable bladder symptoms (18.8%), haematuria (18.1%), fever (>104°F in 12.3%) and stent migration (9.5%) in cases of forgotten stents. They also reported that morbidity and complications were minimal when the stents were kept in situ for less than 3 months, but longer duration stent retention was associated with increased frequency of encrustation, infections, calculus formation and obstruction of the stented tract. A literature search revealed that a stent could remain forgotten upto 8 years post surgery giving rise to various complications [11--13]. In the present case also, the stent was left in the urinary tract for 4 years after removal of the right sided mid ureteric stone and later the part of the stent in the bladder acted as nidus to form a secondary vesical calculus as well as other associated complications like pain abdomen, fever, dysuria, encrustation and vesical calculus formation.

Most stents can be removed under local anesthesia with a two pronged rigid or flexible biopsy forceps. However managing stent complications like struck stents due to long forgotten stent, remained one of the most challenging tasks for the urologists. Those with major proximal stone burden may require percutaneous nephrolithotomy (PCNL) while ureteric fragments can be managed by minimally invasive technique such as ureteroscopy and intracorporeal lithotripsy [14,15]. Forgotten stents should be managed endoscopically only by those who are well trained in advanced Endourology [16,17]. Open surgery has a role where multi model endo-urology procedures fails, but one must remember that this is also not easy and there is danger of renal impairment and sepsis. In the present case, in absence of a qualified urologist, open cysto-lithotomy and removal of the stent and vesical calculus was done under regional anaesthesia. Our report suggests that since the stent is a foreign body, it should not be kept inside the body for longer period. Though the DJ stent has been a boon to the urologists, they should remember the serious complications associated with its use and should not be kept for more than three months. Moreover to avoid prolonged or forgotten stent, surgeon should maintain a diary or a computerized stent log and stress the importance of follow up care by proper counseling and also inform the patient and their attendants regarding presence of a stent and the need for its timely removal.

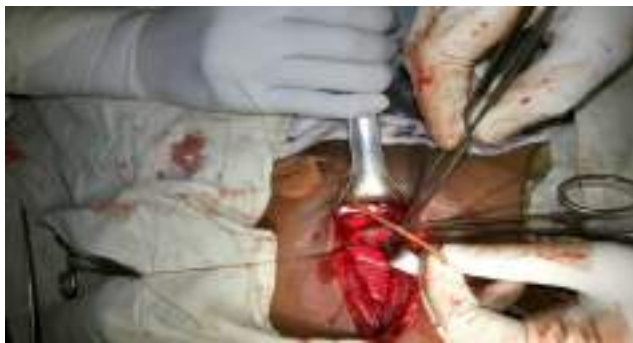

Fig-1 : A Supra-pubic cystolithotomy and removal of encrusted DJ stent.

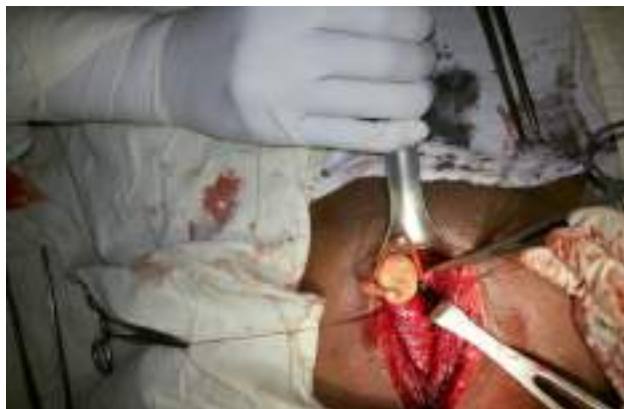

Fig-3 : Suprapubic-cystolithotomy showing encrusted DJ stent



Fig-2 : Encrusted DJ stent with vesical calculus at the tip of stent.

References :

1. Singh I. Indwelling JJ ureteral stents-a current perspective and review of literature. *Indian J of Surg* 2003; 65: 405-12.
2. Nawaz H, Hussain M, Hashmi A, Hussain Z. Experience with indwelling JJ stents. *J Pak Med Assoc* 1993; 43: 147-9.
3. Paz A, Amiel GE, Pick N, Moskovitz B, Nativ O, Potasman I. Febrile complications following insertion of 100 double-J ureteral stents. *J Endourol* 2005; 19: 147-50.
4. Saltzman B. Ureteral stents: indications, variations and complications. *Urol Clin North Am* 1988; 15: 481-91.
5. Pollard SG, Macfarlane R. Symptoms arising from double J ureteral stents. *J Urol* 1988; 139: 37-8.
6. Memon NA, Talpur AA, Memon JM. Indications and complications of indwelling ureteral stenting at NMCH, Nawabshah. *Pak J of Surg* 2007; 23: 187-91.
7. Richter S, Ringel A, Shalev, Nissenkorm I. The indwelling ureteric stent: a 'friendly' procedure with unfriendly high morbidity. *Br J Urol Intl* 2009; 85: 408-11.
8. Singh I. Indwelling JJ ureteral stents-A Current perspective and review of literature, *Indian J.Surg* 2003; 65:405-12.
9. Kehinde EQ, Al-awadi KA, Tawheed A, I-Hunayan A, Ali Y, Mahmood AH. Factors affecting the fate of prolonged forgotten DJ stents *Sc and J Urol Nephrol* 2001; 35: 222-7.
10. Kar A, Angwalo FF, Jhunjhunwala JS. Uretero-arterial and Uretero-sigmoid fistula associated with polyethylene indwelling ureteral stents. *J Urol* 1984; 132:755-7.
11. Hao P, Li W, Song C, Yan J, Song B, Li I. Clinical evaluation of double pigtail stent in patients with upper urinary tract diseases report of 2685 cases, *J Endourol* 2008, 22(i) 65-7.
12. Igujatovic I, Kovic IS, Trapping of double J stent in the urinary tract eight years after extracorporeal shock wave lithotripsy, *Int Urol Nephrol* 2000;32(1)29-31.
13. Chun Kai C, Ching Chia L, Hung Lung K, Yii Her C, Chun-Hsiving H, Ming Chen S, double J stent forgotten for 7 years. A case report. *Kohsiung J Med Sci* 2003; 19(2) 84-7.
14. Perera ND, Wijewardena M, removal of severely encrusted forgotten ureteral stents by minimally invasive technique. *Ceylon Med J* 2002; 47:27.
15. Borborough PG, Kane CJ. Current management of severely encrusted ureteral stents with a long associated stone burden *J Urol* 2000; 164:648-50.
16. Shandera KC, Minimally invasive management of the calcified ureteral stent. *Tech Urol* 1997; 3:54-7.
17. Somers WJ. Management of forgotten retained tn dwelling ureteral stents. *J Urol* 1996; 47:431-5.

Case Report

Dr. Bikash Jyoti Bordoloi¹
Dr. Pradip Kumar Baruah²
Dr. Rajarshi Roy³
Dr. Bikash Agarwal³

Address for correspondence:
Dr. Bikash Jyoti Bordoloi
Email: bbordoloi2020@yahoo.com
Mob: 9864010379



Chronic osteomyelitis of clavicle in an immunocompetent adult: a case report

ABSTRACT

Haematogenous osteomyelitis of clavicle is rare and there is scant literature regarding the behaviour and prognosis of this condition. We present a case of a 25 year old male who had presented to the outpatient department of Orthopaedics in our institute with complaints of pain and discharging sinus for last 4 months. Curettage and sequestrectomy was done. The case is being presented because of its rarity in occurrence.

Key Words : *Clavicle, osteomyelitis; immunocompetent; sequestrectomy.*

Introduction :

Osteomyelitis of long bones is commonly encountered in regular orthopaedic practice but osteomyelitis of clavicle is rare, with an incidence ranging from 0% in mixed-aged population to 7% in children. The mid-portion or medial half of clavicle is a common site of this lesion, although any portion of clavicle can be affected. Chronic osteomyelitis of clavicle usually follows a local invasive procedure; however a primary presentation is possible. Chronic osteomyelitis being a biofilm based infection, surgical intervention is usually required [1]. Proper dead space management combined with prolonged antibiotics can lead to favourable results. The rarity of this condition and the dearth of sufficient literature have prompted us to report this case.

Case Report :

A 25 year old gentleman reported to outpatient department of orthopaedics of our institute with pain and chronic discharging sinus over the right clavicle. He gave a history of trauma to the same site six months back; 2 months later a swelling appeared at the site and had been gradually increasing in size. Incision and drainage was done by general surgeon in some local hospital. On examination, there was serous discharge from right clavicle at the junction of middle and distal third of clavicle with no restriction of movement of the affected shoulder. X- ray showed a sequestrum in the middle third of clavicle with irregular sclerosis and lysis in adjoining areas. The findings were confirmed on a MRI scan. Curettage and sequestrectomy was performed under general anaesthesia and the sample was sent for histopathological examination, PCR for TB and repeat culture sensitivity. The wound healed in 3 weeks

time. The histopathological report showed features consistent with chronic inflammatory changes. PCR for TB was found to be negative. Culture of the pus revealed growth of *Staphylococcus aureus*. The patient has been on follow up for one and a half year. There are no complaints or any movement restrictions at present.

Figure 1: pre operative and post operative wound

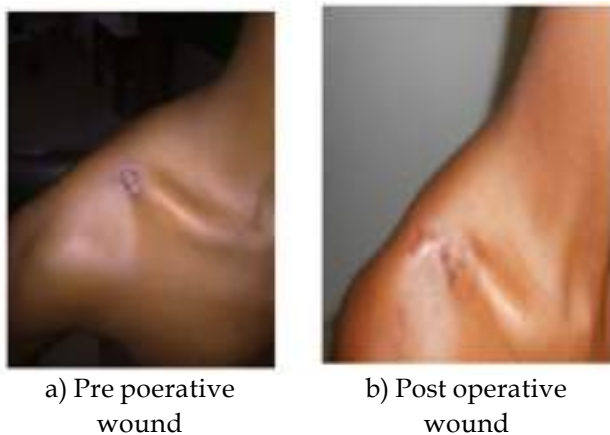
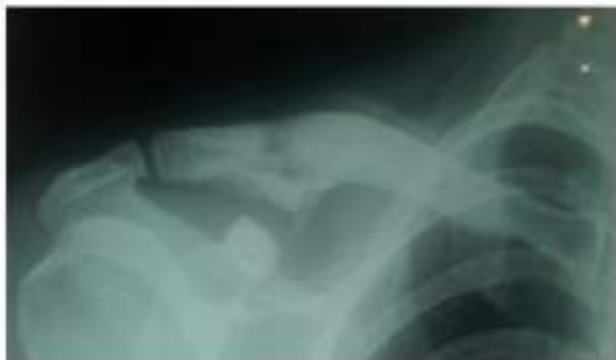

Figure 2 : pre operative radiograph



Discussion :

Primary hematogenous osteomyelitis is more commonly a disease of childhood; affecting the ends of long bone. In adults it usually involves the vertebra due to its sluggish blood flow and valveless Batson's plexus of veins. Osteomyelitis of the clavicle in adults is a rare occurrence. When it occurs, it usually is secondary to a local invasive procedure. It has been reported following head and neck oncosurgeries, pacemaker implantation and subclavian vein catheterisation [2,3]. Chronic osteomyelitis following internal fixation also has been reported [4]. Predisposing factors include immunosuppression, diabetes mellitus and reduced vascularity.

Damodaran et al presented a case of primary haematogenous osteomyelitis in a patient with IgA nephropathy [5]. However, IgA nephropathy can lead to chronic renal failure; thus the patient could have been in an immunosuppressed state. Chaudhury et al presented a case of primary hematogenous osteomyelitis of clavicle in an immunocompetent adult [6].

The pathogenesis of acute osteomyelitis is well described. In the acute stage vascular compromise occurs. An unfavourable response to treatment results in sequestration which forms the nidus for biofilm formation. Chronic osteomyelitis is a biofilm based infection where organisms are sessile in nature rendering them less susceptible to antibiotics and phagocytosis [1]. Surgical intervention remains the most effective means of treatment in this setting.

The organisms found in osteomyelitis are *S. aureus* in 80% of the cases. Other commonly cultured bacteria include *Klebsiella* and *Staphylococcus epidermidis*.

In acute osteomyelitis, the patient usually presents with pain, fever or localized swelling. Other symptoms include stiffness of the nearby joints. A history of prior trauma and/or local surgical procedures may be elicited. Chronic osteomyelitis may present with a history of prior infections and a draining sinus or extrusion of necrotic bone [1].

Plain x-ray may reveal widening of the bony cortex and joint, irregular destruction, a moth eaten appearance, periosteal new bone formation and thickening. A sclerotic or lytic appearance may be observed. MRI is more specific and sensitive in distinguishing osteomyelitis. HIV screening is done to look for immune status.

Our patient being an immunocompetent person with localised disease is being categorised as stage III (localised not threatening stability) A (immunocompetent host) according to Cierny and Madder staging [7]. Accordingly, scar excision, sequestrectomy and superficial decortications were done. Integrity of the residual bone was intact and minimal dead space was eliminated with approximation of surrounding viable soft tissues. Antibiotics were continued upto 6 weeks. Eventually wound healed and CRP came down to normal at 12 weeks. At one and a half year follow up, the patient is symptom free with full range of movement in shoulder.

Conclusion :

Primary osteomyelitis of clavicle in an immunocompetent patient is a rare occurrence. Chronic osteomyelitis are biofilm based infections. Surgical debridement is the most effective means of treatment. Reconstruction depends on dead space created and integrity of the residual bone. Effective surgical management with prolonged antibiotics can lead to good results.

Bibliography :

1. Donlan RM, Costerton JW. Biofilms: survival mechanisms of clinically relevant microorganisms. *Clin Microbiol Rev*, 2002; 15(2):167-193.
2. Alessi DM., Sercarz JA., Calcaterra TC. Osteomyelitis of the clavicle. *Arch Otolaryngol Head Neck Surg* 1988; 114:1000-2.
3. Krespi YP, Monsell EM, Sisson GA. Osteomyelitis of the clavicle. *Ann Otol Rhynol Laryngol* 1983; 92:525-7.
4. Balakrishnan C, Vashi C. Post traumatic osteomyelitis of the clavicle: A case report and review of literature. *Can J Plast Surg* 2008;16(2):89-91.
5. Damodaran A, Rohit A, Abraham G et al. Case report: rare occurrence of *Pseudomonas aeruginosa* osteomyelitis in the right clavicle in a patient with IgA nephropathy [v1; ref status: indexed, <http://11000r.es/37r>]nF1000Research 2014; 3:268 (doi: 10.12688/f1000research.3891.1).
6. Chaudhary P. Chronic osteomyelitis of clavicle. *Health Renaissance* 2011; 9(2):125-7.
7. Cierny G, Mader JT, Pennick JJ. A clinical staging for adult osteomyelitis in adults. *Clin Orthop Relat Res*. 2003; 414:7-24.

Compiled by:
Editor

1. Boiled coffee consumption and the risk of prostate cancer: follow-up of 224,234 Norwegian men 20-69 years

British Journal of Cancer, 12/24/2014 Clinical Article

Tverdal A - There is insufficient epidemiological evidence on the relationship between type of coffee and the risk of prostate cancer. An inverse relationship between number of cups per day and the risk of prostate cancer was present only for the boiled coffee type.

Methods:

- The risk of prostate cancer by use of boiled vs not boiled coffee were assessed in a prospective study of 224,234 men 20-69 years.
- 5740 incident prostate cancers were identified.

Results :

- With no coffee as reference group the hazard ratios of <1-4, 5-8 and 9+ cups per day of boiled coffee only were 0.84 (0.73-0.96), 0.80 (0.70-0.92) and 0.66 (0.55-0.80), P-trend=0.00.
- The corresponding figures for not boiled coffee were 0.89 (0.80-0.99), 0.91 (0.81-1.02) and 0.86 (0.74-1.00), P-trend=0.22.

2. Laparoscopic vertical sleeve gastrectomy significantly improves short term weight loss as compared to laparoscopic adjustable gastric band placement in morbidly obese adolescent patients

The Prostate, 01/27/2015 Cook MB, et al.

Within the U.S., there exists significant geographic variability in prostate cancer incidence rates. Although there are large geographic differences in BWIRRs, temporal trends are fairly stable. This may indicate that primary factors affecting prostate cancer incidence rates vary geographically but affect both black and white men to a similar degree.

Methods

- Prostate cancer counts and population denominators by race (black, white), age, calendar year, and U.S. census division, for the period 1999-2008, were extracted from NPCR and SEER.
- Authors calculated age-standardized incidence rates (ASR) and estimated annual percent changes (EAPC) by race and census division.
- They assessed black-to-white incidence rate ratios (BWIRR) by census



division and by calendar period.

Results

- This analysis included 1,713,471 prostate cancer cases and 1,217 million person-years.
- Black ASRs ranged from 176 per 100,000 person-years in Mountain division to 259 in Middle Atlantic.
- BWIRRs ranged from 1.20 in Western divisions to 1.72 in Southeastern divisions.
- EAPCs indicated that prostate cancer incidence is not decreasing in East South Central, unlike all other divisions.
- White EAPCs displayed similar variations by census division, resulting in modest temporal changes in BWIRRs.

3. Morbidity after Total Gastrectomy: Analysis of 238 Patients

Luke V. Selby, Emily A. Vertosick, Daniel D. Sjoberg, Mark A. Schattner, Yelena Y. Janjigian, Murray F. Brennan, Daniel G. Coit, Vivian E. Strong,

Journ of the American College of Surgeon. DOI: <http://dx.doi.org/10.1016/j.jamcollsurg.2015.01.058>

Background

Surgical quality improvement requires well-defined benchmarks and accurate reporting of postoperative adverse events, which have not been well defined for total gastrectomy.

Study Design

Detailed post-operative outcomes on 238 patients who underwent curative intent total gastrectomy from 2003 - 2012 were reviewed by a dedicated surgeon chart reviewer to establish the 90-day patterns of adverse events.

Results

Of the 238 patients with stage I - III gastric adenocarcinoma who underwent curative intent total gastrectomy, the median age was 66, and 68% were male. Median body mass index was 28, and 68% of patients had at least one medical comorbidity. Forty three percent of our patients received neoadjuvant chemotherapy, and 34% received post-operative adjuvant chemotherapy. Over the 90 day study period, 30-day mortality was 2.5% (6/238), and 90-day

mortality was 2.9% (7/238). At least one post-operative adverse event was documented in 62% of patients, with 28% of patients experiencing a major adverse event requiring invasive intervention. The readmission rate was 20%. Anemia was the most common adverse event (20%), followed by wound complications (18%). The most common major adverse event was esophageal anastomotic leak, which required invasive intervention in 10% of patients.

Conclusions

This analysis has defined comprehensive 90-day patterns in post-operative adverse events following curative intent total gastrectomy in a Western population. This benchmark allows surgeons to measure, compare, and improve outcomes and informed consent for this surgical procedure.

4. Tumor factors predictive of response to hypofractionated radiotherapy in a randomized trial following breast conserving therapy

Annals of Oncology, 03/03/2014 Bane AL, et al.

This study aims to determine whether tumor grade, molecular subtype and hypoxia predict response to hypofractionated vs. standard radiotherapy (RT) following breast conserving surgery (BCS) for node negative breast cancer in a randomised controlled trial (RCT). In women enrolled in the HWBI trial following BCS tumor molecular subtype predicted LR. However tumor grade, molecular subtype and hypoxia did not predict response to hypofractionation suggesting that patients with node negative breast tumors of all grades and molecular subtypes may be safely treated with hypofractionated RT regimens.

Methods

- Formalin fixed paraffin embedded (FFPE) tumor blocks were available on 989 of 1234 patients enrolled in the Hypofractionation Whole Breast Irradiation (HWBI) Trial.
- A central pathology review and assessment of tumor grade using the Nottingham grading system was performed.
- Tumors were classified by molecular subtype as luminal A, luminal B, HER2 enriched, basal-like or unclassified using a six-biomarker panel; ER, PR, HER-2, Ki67, CK5/6 and EGFR.

- Tumors were also classified as hypoxic based on the expression of HIF1?, CAIX or GLUT-1.
- The primary end point was local recurrence (LR).

Results

- Median follow-up was 12 years.
- In the multivariable Cox model molecular subtype was the only factor predictive of LR, the 10 year cumulative incidence was 4.5% for luminal A and basal-like, 7.9% for luminal B and 16.9% for HER-2 enriched tumors ($p < 0.01$).
- Tumor grade, molecular subtype or hypoxia did not predict response to hypofractionation.

Association News

HON. SECRETARY'S REPORT from ASSAM STATE CHAPTER of ASI

Respected esteemed members of Association of Surgeons of Assam (Assam State Chapter of ASI),

Rongali Bihu Greetings to you all. It gives me immense pleasure in presenting before you the brief report of our chapter till March, 2015.

Present executive committee led by our senior and active member Dr. R.N.Mazumder was elected during our silver jubilee annual conference held last year from 7th to 9th November, 2014 and officially took over charge on January 10th,2015. at a function held at our chapter office , Guwahati. On the same they we sat for our first executive body meeting and planned future activities of our chapter along with a tentative academic calendar for the coming year.

I like to highlight before you the activities of our Association during this short span of time.

The SILVER JUBILEE ANNUAL CONFERENCE of Assam chapter "ASACON 2015" was held at Guwahati Medical College, Guwahti, Assam from 7th to 9th November 2014. It was a memorable event with full of academics, surgical workshop and hands on training courses under the guidance and active participation of eminent national and local faculties. I take this opportunity to thank our immediate past President Dr. Satish Sukla sir for his gracious presence and encouragement during the session.

Dr.G C Jain, Past President of ASA and former GC member of ASI was accorded, during last conference with "Life time achievement award" for his contribution to the society and growth of the association by Assam Chapter for the year 2014.

At the initiative and continuous stimulation of Dr.Santhosh John Abraham, President of the Association of Surgeons of India, the Guwahati city branch, along with Assam State Chapter had organised ASI North East Zonal CME on 7th & 8th March'15. Surgeons and post graduate students from all the north eastern states had attended the event. The two days programme consisted with PG master Class, CME lectures by eminent teachers of medical Institutions from all over the country and NE region in particular. A competition paper and e poster presentation session was conducted amongst the students. The best e poster was presented by Dr.Sandeep Ghose from NEIGRIMS, Shillong and the best free paper was presented by Dr.Babitha N from RIMS, Imphal. In the talent hunt competition (ASI TYSA), Dr.Abhisekh Patil from Silchar Medical College, Assam has been qualified to participate in the national level representing North eastern zone. One hundred and eighty registered delegates attended the programme and all the delegates and faculty were awarded with CME credit hours as per MCI guideline.

Nagaon Branch of The Association of Surgeons of Assam organized a CME on 25th October 2014 at Nagaon. The Scientific session was moderated by Dr. K.N. Goswami and Dr. J.N. Gohain. The presentation started with video presentation starting from simple laparoscopic cholecystectomy to advanced laparoscopic Nephrectomy by Dr. Foridul Hussain. He also presented on advanced technique of TURP and shared some of his experiences. Dr. M.A. Sarkar made a presentation on different aspects of etiology, diagnosis and plan of treatment of pancreatitis.

Dr. R.N. Majumder, Chairman Assam Chapter chaired a session on Burn Care and Prevention organized by burn care foundation, Guwahati held on 14th Feb. 2015.

Our Tezpur city branch has organized a seminar on 15th. Feb 2015. and our Chairman Dr. R.N. Mazumder was present during the session to encourage activities of the branch. Different aspects of Bariatric surgery and

latest development of laparoscopic Hernia repair were discussed by Dr. Manoj Choudhury and S A Majid respectively as faculty members in presence of a large gathering.

Dibrugarh branch has organized a seminar on 12 December, 2014 at Dibrugarh with special focus on urological aspect of surgery. Few case reports on Intra-testicular Rhabdomyosarcoma, Urachal Cyst, Pheochromocytoma and Uncommon Foreign Body in urinary bladder were presented by the faculties and post graduate students. The seminar was well attended by members and eminent surgeons from the region.

Our undivided Sibsagar District Branch organised two seminars jointly with Doctors' club, Jorhat, at Jorhat - one on 23rd Jan, 2015 on " Management of Haemorrhoids - Medical, Surgical and Controversies and the other on 7th Feb, 2015 on Surgical management of Chronic Pancreatitis and the Speakers were Dr. Kamal Chandra Dey from same chapter and Dr. Pranjal Deka, M.Ch. GI Surgery from Guwahati respectively. An audio visual presentation on Medico legal Issues was also presented during the session. Our member Dr. S.J.Das delivered a public awareness speech at Cancer Awareness programme organized by Concept Junior College, Titabor, on the occasion of World Cancer Day.

Most recently 3rd Advanced Laparoscopic Surgery Workshop cum CME was organized by Nazareth Hospital, Shillong, Meghalaya, in collaboration with Meghalaya surgical Association, Association of Surgeons of Assam and Association of Minimal Access Surgeons of India (AMASI) on 28th and 29th. March 2015. We feel proud to be a part of this academic bonanza.

Recently on 24th Feb., 2015 we lost our beloved past President of our chapter retired Professor Dr. S.B. Dutta Choudhury creating a vacuum in the entire north eastern part of India.

In the mean time, we have prepared an academic calendar for next part of our tenure, which includes different public awareness programme to enable us to reach the populace, besides holding annual conference at Jorhat & midterm CME at Hojai, Surgical workshops and branch CMEs at different branches involving more and more member including members from the periphery. We have also included awareness programme to popularise national welfare programme like male sterilisation procedure (like vasectomy /NSV) in a bid to discharge our responsibility towards country's welfare & development. We have planned to work for enrolment of new ASI members from our state.

We are regularly publishing a quarterly Journal named JASA of high Standard which is recently indexed in Copernicus and Indian Citation Index. Special thanks to Editor and Editorial board of JASA for this achievement. The news letter "Surgery Papyrus" started last year will be continued as quarterly publication.

Before I conclude, let me offer my sincere thanks to you all for selecting me as Hon Secretary of the Association. We seek your co operation, guidance and suggestions to serve our dear Organisation better.

Thanking you all

Dr. Pulakananda Bharali
Hon. Secretary.
Assam Chapter of ASI

Journal of Association of Surgeons of Assam

p-ISSN: 2347-811X

Journals's original version: printed version

BASIC INFORMATION

p-ISSN: 2347-811X

e-ISSN: none

Prefix of DOI number: none

Journals's original version: printed version

Title in original language:

Journal of Association of Surgeons of Assam

Title's language: English

English title:

The Journal of Association of Surgeons of Assam

Short title: JASA

Former title:

JASA

Journal's country of origin: India

Affiliation:

Association of Surgeons of Assam, India

Journal's website:

<http://www.asiassam.org>

Describe journal's profile in English (max. 1500 characters): scientific

Frequency of issuance: Quarterly

Circulation: 1000 copies

Licence on which journal makes its articles available:

free for non-commercial use

Full-text research articles availability: free

DISCIPLINES

Main science field describing journal:

Natural science

Social sciences

Humanities

No

No

Yes

Disciplines corresponding with journal's subject area:

Medical science -- Medicine -- Surgery;

EDITORIAL OFFICE

No Editorial office member was given

Editorial office address:

Assam Medical College & Hospital, Department of Paediatric Surgery
Assam Medical College campus
P.O. Borbari, PIN-786002., Dibrugarh
Assam
India
Email: hemontdut@gmail.com
Tel: +913732301524

PUBLISHER

Association of Surgeons of Assam, Dept. of Surgery, Gauhati Medical College

Bhangagarh
p.o. Gauhati Medical College, PIN- 781 Guwahati
Assam
India
email: hemontdut@gmail.com
tel: +913732301524
www: www.asiassam.org

SCIENTIFIC QUALITY

How many original research articles have been published over the past two years?

2013: 14
2012: 12

How many research articles have been published over the past two years?

2013: 25
2012: 23

Impact Factor value:

no answer

Disciplines corresponding with journal's subject area according to Journal Citation Reports classification

not applicable

In which scientific databases is journal indexed?

AGRO	No
Astrophysics Data System (ADS)	No
BazHum	No
BazTech	No
Biological Abstracts	No
BIOSIS Preview/BIOSIS	No
Cambridge Scientific Abstracts (CSA, Proquest)	No
CEEOL (Central and Eastern European Online Library)	No
CEJSH	No
Chemical Abstracts (CAS)	No
Dialnet	No
DOAJ	No
E-revistas	No
EBSCO	No
EMBASE	No
Genamics	No
IC Journals Master List	No
INSPEC	No
ISI Web of Science (WoS)	No
JSTOR	No
Medline/Pubmed	No
Scopus	No
Ulrich's periodicals	No
Worldcat	No
ZBD	No
Zoological Rekord	No

INTERNATIONALIZATION

Specify languages in which titles and abstracts are published.

Original language: English English
Other congress languages: no answer

Specify languages in which articles are published.

Original language: English
Other congress languages: no answer

What percentage of an Editorial Board members are international members?

15 %

What percentage of journal reviewers are international reviewers?

10 %

What percentage of authors of research articles have foreign affiliation?

10 %

STABILITY

Date of journal's first edition (year).

1993

Has there been at least one combined issue of a journal over the past two years?

No

Has there been an editorial delay of more than 6 months over the past two years?

No

Has there been at least one issue of a journal published over the past two years?

Yes

TECHNICAL QUALITY

Does journal have DOI (Digital Object Identifier) number?

No

Are full-text research articles published in a journal available online?

At least some full-text research articles published in a journal are available online.

Are research articles published in a journal available in Google Scholar?

No

In what file format is journal's content available online?

HTML: No

PDF: No

XML: No

What tools for managing bibliographic information is made available by a journal?

BibTeX: No

EndNote: No

RefMan: No

RefWorks: No

other: No

What bibliographic styles do journal use?

APA: No

Chicago: No

MLA: No

IEEE: No

other: No

Does a journal have a website?

No

Does a journal have a browser on its website?

Option to browse journal's number:

No

Option to browse key words:

No

Option to browse publications' authors:

No

Option to browse publications' title:

No

STANDARDS
Does journal have a reviewing procedure described in detail on original version? Yes
What percentage of journal reviewers are external reviewers? 20 %
Which reviewing procedure model is used by a journal? double blind model
Does Editorial office require: authors to submit publication originality statement? Yes authors to clearly specify the authors' contributions (ghostwriting prevention)? Yes authors to submit conflict of interest statement? Yes authors to submit sources of financing statement? No
Does a journal have clearly specified subject area? Yes
Does a journal have clearly specified information on copyrights? Yes
Does a journal have clearly stated standards of preventing scientific dishonesty? Yes
Does every article have its own licence? No
Does a journal have clearly specified standards of copyright transfer? No