

www.asiassam.org

Volume 30 | No 1 | June 2023- October 2023

ISSN 2347-811X



JASA

Official Journal of Assam State Chapter of ASI

JASA

The Journal of
Association of Surgeons of Assam

JASA, The Journal of Association of Surgeons of Assam

JASA, The Journal of Association of Surgeons of Assam (Assam Chapter of Association of Surgeons of India), Vol 30, No. 1, June 2023-October 2023, Edited by Dr. Debabrata Dutta and Published by the Association of Surgeons of Assam, Guwahati 781032, Assam. The opinions expressed and conclusions drawn in the articles are those of the authors solely and not necessarily reflections of the editorial board or publisher of JASA.

The Journal of Association of Surgeons of Assam (**JASA**)

Volume 30, No. 1, June 2023 to October 2023

Design & Layout

Moonlit Printers, R.G.B. Road, Guwahati-24

E-mail : moonlitprinters@rediffmail.com

Mobile : 90850 18333

Correspondence :

Editorial Office :

House No. 4, Ambikagiri Nagar, R. G. B. Road, Guwahati-781024

Near Sankardev Sishu Kunja, 5th Bye Lane (South)

Email : drdebaassam@gmail.com



The Journal of Association of Surgeons of Assam (ASA)

Official Journal of Assam Chapter of Association of Surgeons of India (ASI)

Editor : Dr. Debabrata Dutta

Editorial Board Members

Dr Kanakeswar Bhuyan, Guwahati
Dr Dipak Kumar Sarma, Guwahati
Dr N. N. Ganguly, Jorhat
Dr S. S. Bhattacharjee, Silchar
Dr Manoj Saha, Guwahati
Dr Jishan Ahmed, Dibrugarh

Editorial Consultants

Dr. S. Khanna (Minimally Invasive and Bariatric Surgery)
Dr. M.K. Choudhury (G.I. and Minimally Invasive and Bariatric Surgery)
Dr. N.C. Bhattacharyya (Neonatal and Paediatric Surgery)
Dr. Seema Rekha Devi (Burns and Plastic Surgery)
Dr. Sumitra Hagjer (General and Minimally Invasive Surgery)
Dr. P. M. Deka (Urology and uro-endoscopy)
Dr. J. N. Buragohain (Surgical Oncology)

The Journal of Association of Surgeons of Assam

Official Journal of Assam State Chapter of ASI

Contents & Contributors

<u>Editorial</u>	Dr. Debabrata Dutta	
<u>Original Articles</u>		
Guest Author :	Intervention for Painful Chronic Pancreatitis: Surgery or Endotherapy?	1
	Dr. Rupjyoti Talukdar	
	Holistic Approach for Management of Common Bile Duct Stones in a Single Institute in a period of 5 years - A Retrospective Study	4
	Dr. Shapam Kiran Singh, Dr. N. N. Das	
	Urological dual Pathology Managed Laparoscopically– A Series of 3 Cases.	10
	Dr. Debanga Sarma	
	Abdominal wound Dehiscence : Predicting Factors and Evaluation of Management Strategies	15
	Dr. Shardha Srinivas, Dr. Kanakeswar Bhuyan	
	Approaches to Few Common Paediatric Surgical Conditions: General Surgeon's Perspectives	20
	Dr. Manoj Saha	
<u>Review Article :</u>	Head Injury: Prognosticators- and Basic Management	31
	Dr Rajesh Kumar Barooah	
<u>Case Reports :</u>	A Case Report on a Rare Case of Teratoma Involving Adrenal Gland	36
	Dr. Faridul Hussian, Dr. Prabal Deka	
	A Rare Presentation of Chronic Cholecystitis - Cholecystocutaneous Fistula-A Case Report	39
	Dr. Bibhu Priyo Das, Dr. Subash A Ragupathy	
	A Rare Case Report of Retroperitoneal Schwannoma	43
	Dr. Ravi Shankar S, Dr. Hiranmoy Das, Dr. Rajesh Kumar Barooa, Dr. Ridip Mazumder	

Editorial

"Pen is mightier than the sword". This universal proverb that has been echoing for centuries. Yes it is and it should be forever. But in some lonely moments, several absurd thoughts try to roam in my grey matter..... Is it true for a surgeon??

Still the answer may be "Yes"; but with so many advances in the surgical domain like Endoscopy, Laparoscopy, Robotics, Artificial intelligence, Nano-technology etc. etc., if we engage ourselves in instrumentation (sword) only, there will remain a gap between service and knowledge sharing.

I think for a surgeon, 'Sword' and his elaborative and evidence based 'Pen' are equally important for future generation as well as to mankind. Pen is the bridge between sharing and caring.

" JASA" also for last several years is trying hard to contribute a Big drop in the vast ocean of knowledge. It has justified its presence as the 'Face book' for the surgical fraternity of the whole N. E. region of India.

*"Change is the need
Change in time is the progress"
_____anonymous*

Bygone Covid era has tremendously changed our thought proceses and perceptions. Not only surgeons, but the whole medical community has polished themselves to be a writer or a compiler or digital explorer. Our record-keeping habit is too developed to a great extent. Hope it is beginning of a new dawn. We are gradually training our mind for a good grip of our " Sword" and our "Pen". This will definitely take our forum to a new horizon.

As a newly appointed editor of this pioneer and prestigious Journal of Association of Surgeons of Assam, I have faced many hurdles regarding the delivery of this Journal to our forum. But immense help and guidance of my respected seniors and contributors have lessen the labour pain to a large extent. My humble regards to all of you.

Long live ASA
Long live JASA



Dr. Debabrata Dutta



Intervention for Painful Chronic Pancreatitis: Surgery or Endotherapy?

Dr. Rupjyoti Talukdar

MD, FICP, AGAF, FISC, FRCP, FRSB

Director, Pancreatology

Clinical Pancreatologist and
Clinician Scientist

Asian Institute of Gastroenterology,
Hyderabad

Head, Pancreas Research Group & Division of Gut Microbiome Research

Wellcome-DBT India Alliance Labs.,
Institute of Translational Research,

Asian Healthcare Foundation,
Hyderabad

Adjunct Faculty, Johns Hopkins
University, Maryland, USA

J Assoc Surg of Assam 2023; 1 : 1-3

JASA

The Journal of Association of
Surgeons of Assam

Volume 30, No. 1

June 2023 to October 2023

Introduction:

Chronic pancreatitis (CP) is clinically characterized by recurrent intractable abdominal pain, malnutrition due to multifactorial reasons including exocrine insufficiency, and endocrine dysfunction¹. Of these, pain is the most debilitating manifestation that drives the patient to medical attention. However, it is important to appreciate that up to 10% of patients with may never have abdominal pain.

There is still no definitive treatment for CP and whatever treatment measures are taken are at best palliative or supportive with an aim to allay symptoms. The mainstay of treatment for pain in CP are medical therapy (antioxidants, neuromodulators), endoscopic therapy (ERCP with PD stenting, ESWL), and surgery (resection surgery such as Whipple's operation and distal pancreatectomy; and drainage procedures such as LPJ or Frey's operation).

Pain mechanisms in CP :

Pain in CP is multifactorial, and several independent yet overlapping mechanisms could be responsible for pain in CP². During the initial stages of the disease, as recurrent clinical and subclinical inflammation develops, there will be activation of various nociceptors namely PAR-2, TRPV1, TRK, on the intrapancreatic pancreatic nerves³. As the disease progresses, there will be sensitization of the spinal segments of the pancreatic dermatome, which will gradually progress to the other dermatomes. The former is known as segmental sensitization while the latter widespread sensitization⁴. The phenomenon of widespread sensitization is a part of pancreatic neuropathy, which is also characterized by neural reorganization within the areas of the brain such as the hippocampus, prefrontal cortex, anterior cingulate cortex, and basal ganglia, that modulate long term pain memory, pain behavior, and emotional responses to pain⁵. As the disease progresses, there is also depression and associated changes in metabolites in the hippocampus which could also correlated well with the degree of pain⁶. A composite of all these factors will result in the ultimate pain experience and perception in by the patient with CP, which may be independent of the disease morphology.

Endotherapy for pancreatic pain ⁷:

Pancreatic endotherapy is conducted for painful pancreatic duct (PD) stone includes ERCP with pancreatic sphincterotomy and stone extraction, ESWL with or without PD stenting, and sphincterotomy and PD stenting (predominantly for PD stricture). Some centers also perform pancreatic sphincteroplasty for prior to extraction of pancreatic ductal stone. ERCP and stone extraction is best suited for ductal stones that are smaller than 3-5mm in size and located in the head, neck, or proximal body region. For stones larger than 5 mm in the head, neck and proximal body, the ideal modality is ESWL followed by PD stenting if the stone burden is high. However, ESWL should not be done if the stones are distributed throughout the pancreatic duct, if there is gross ascites or if there are local complication such as duodenal obstruction, large pseudocyst in the line of ESWL, and pancreatic mass lesions (inflammatory or neoplastic). In these latter situations, results of ESWL are not favorable and risks of complications are high. Therefore, these patients should be referred upfront for surgery.

Surgery for pancreatic pain :

A detailed description on the surgical techniques is out of the scope of this article. Surgery should be the first choice of therapy if CP is associated with pancreatic ductal stones, local complications such as presence of concomitant biliary strictures, multiple PD strictures, strictures in the upstream PD, and mass lesions.

Is it surgery or endotherapy first for painful PD stones?

It has traditionally been perceived, more so by the surgical community, that surgical management should be the gold standard for treatment of painful ductal stones or strictures. However, if we look at the results of the randomized controlled trial by Cahen et al., even though in the first 2 years of follow-up the primary outcome of Izbicki pain score significantly improved in the surgical arm, on 5 years follow-up that significance was no longer seen^{8,9}. Even in the more recent Escape trial from the Dutch Pancreatitis Study Group, even though surgery appeared better than ESWL for the treatment of pan-

creatic ductal stones, the authors themselves mentioned that there could have been subjectivity bias on the pain scores, placebo effect could not be measured as there was no sham arm, secondary effects could have been underpowered, and the results may not be applicable to centers with lower expertise¹⁰.

Even after total pancreatectomy for CP, it has been observed that up to 40% of patients could still have pain despite removal of the entire pancreas.

In the case of endotherapy also, ESWL studies in which patients were followed for a shorter duration (6-12 months) showed greater than 80% response rate while in the studies where patients were followed longer (around 5 years), their pain response rate reduced to lower than 60%^{11,12}.

These observations clearly imply that pain in CP could change dynamically over time and extra-pancreatic mechanisms are equally important which could reduce the durability of the currently available interventional treatment, be it surgery or endotherapy. Therefore, surgery and endotherapy could be complimentary to each other both having their advantages and disadvantages.

Points to consider before selecting the interventional treatment modality:

To get the best possible outcomes from any intervention, the most important aspect if to assess is the patient will be benefitted by any interventions at all. Any kind of interventions should be avoided is the patient has a painless disease and there are no local complications. For the painful patients, it is extremely important to assess the pain phenotype. The pain characteristics (continuous, pain triggers, involvement of new areas, new areas of radiation) and psychological status should be carefully evaluated before deciding to undertake any intervention. Patients with long standing disease, having characteristics of neuropathic pain (continuous pain, involvement of new areas, change in pain character over time) and significant anxiety/depression is unlikely to have a durable response to both surgery and endotherapy.

It is important to evaluate the pancreatic morphology before deciding on the interventional modality for patients with painful ductal stones or strictures. As already mentioned above,

patients with painful ductal stones or strictures. As already mentioned above, patients having obstructive painful ductal calculi in the head, neck and proximal body region would respond well the ESWL or ERCP and stenting (based on stone size and density). Endotherapy should be the first line of interventional management in these patients. On the other hand, patients with stones all along the PD, multiple PD strictures, concomitant non-resolving distal biliary strictures, and local complications such head mass, duodenal obstruction, multiple strictures, should be taken up for surgery as the primary treatment.

Availability of expertise and patient's choice are also important components that needs to be considered while deciding on the interventional treatment modality.

Conclusion:

Pain in CP is multifactorial and requires interdisciplinary treatment. Both surgical and endoscopic interventions are available for treatment of painful PD stones and structures. However, the long-term durability of both surgical and endoscopic therapy is questionable, and pain tends to recur in a majority of these patient over time. Therefore, it is important to assess the pain characteristics, psychological status, disease duration, disease morphology, availability of expertise and patient's choice before deciding on a particular interventional modality (surgery or endotherapy) for painful chronic pancreatitis.

Reference:

1. Talukdar R, Reddy DN. Pain in chronic pancreatitis: managing beyond the pancreatic duct. *World J Gastroenterol*. 2013 Oct 14;19(38):6319–28.
2. Talukdar R, Nageshwar Reddy D. Is there a single therapeutic target for chronic pancreatitis pain? *Gastroenterology*. 2013 Mar;144(3):e18.
3. Xu GY, Winston JH, Shenoy M, Yin H, Pendyala S, Pasricha PJ. Transient receptor potential vanilloid 1 mediates hyperalgesia and is up-regulated in rats with chronic pancreatitis. *Gastroenterology*. 2007;133:1282-1292.
4. Drewes AM, Krarup AL, Detlefsen S, Malmstrøm ML, Dimcevski G, Funch-Jensen P. Pain in chronic pancreatitis: the role of neuropathic pain mechanisms. *Gut*. 2008; 57:1616-1627.
5. Dimcevski G, Sami SA, Funch-Jensen P, Le Pera D, Valeriani M, Arendt-Nielsen L, Drewes AM. Pain in chronic pancreatitis: the role of reorganization in the central nervous system. *Gastroenterology*. 2007;132:1546-1556.
6. Sarkar S, Sarkar P, M R, Hazarika D, Prasanna A, Pandol SJ, Unnisa M, Jakkampudi A, Bedarkar AP, Dhagudu N, Reddy DN, Talukdar R. Pain, depression, and poor quality of life in chronic pancreatitis: Relationship with altered brain metabolites. *Pancreatolgy*. 2022 Sep;22(6):688-697.
7. Manu Tandan, Rupjyoti Talukdar, D. Nageshwar Reddy. Management of pancreatic calculi: an update. *Gut and Liver* 2016; 10: 873-880.
8. Cahen DL, Gouma DJ, Nio Y, Rauws EA, Boermeester MA, Busch OR, Stoker J, Laméris JS, Dijkgraaf MG, Huibregtse K, Bruno MJ. Endoscopic versus surgical drainage of the pancreatic duct in chronic pancreatitis. *N Engl J Med*. 2007 Feb 15;356(7):676-84.
9. Cahen DL, Gouma DJ, Laramée P, Nio Y, Rauws EA, Boermeester MA, Busch OR, Fockens P, Kuipers EJ, Pereira SP, Wonderling D, Dijkgraaf MG, Bruno MJ. Long-term outcomes of endoscopic vs surgical drainage of the pancreatic duct in patients with chronic pancreatitis. *Gastroenterology*. 2011 Nov;141(5):1690-5
10. Issa Y, Kempeneers MA, Bruno MJ, Fockens P, Poley JW, Ahmed Ali U, et al. Effect of Early Surgery vs Endoscopy-First Approach on Pain in Patients With Chronic Pancreatitis: The ESCAPE Randomized Clinical Trial. *JAMA*. 2020 Jan 21;323(3):237-247.
11. Tandan M, Reddy DN, Talukdar R, Vinod K, Santosh D, Lakhtakia S, Gupta R, Ramchandani MJ, Banerjee R, Rakesh K, Varadaraj G, Rao GV. Long-term clinical outcomes of extracorporeal shockwave lithotripsy in painful chronic calcific pancreatitis. *Gastrointest Endosc*. 2013; 78: 726-33.
12. Manu Tandan, D. Nageshwar Reddy, Rupjyoti Talukdar, Vinod K, Kiran SVVS, Santosh D, Gupta R, Ramchandani M, Lakhtakia S, Rakesh K, Manohar Reddy P, Basha J, Nabi Z, Jagtap N, Rao GV. ESWL for large pancreatic stones: report of over 5000 patients. *Pancreatolgy*, 2019; Aug 2: doi: 10.1016/j.pan.2019.08.001.



Dr. Shapam Kiran Singh

DNB-PGT General Surgery, down town Hospital, Dispur, Guwahati, Assam,

Dr. N. N. Das

Senior Consultant
Department of Surgical Gastroenterology,
down town Hospital, Guwahati

J Assoc Surg of Assam 2023; 1 : 4-9

JASA

The Journal of Association of Surgeons of Assam
Volume 30, No. 1
June 2023 to October 2023

Holistic Approach for Management of Common Bile Duct Stones in a Single Institute in a period of 5 years A Retrospective Study

ABSTRACT

Background: Management of common bile duct stones (CBDS) continue to pose the greatest challenge to the surgeons

Methods: A total of 213 patients who were admitted in admitted in the Department of Surgery, Down Town Hospital, Guwahati, Assam during the period of January 2018 to December 2022 were studied. The diagnosis was made using clinical symptoms, USG MRCP, relevant blood investigations. Patients were managed on the basis of radiological findings by the best possible way and expertise available.

Results : Out of the 213 patients, 77 (36.15%) were male and 136 (63.84%) were female. The mean age for male was 50.92 years and for female, it was 51.74 yrs. Patients are managed either by ERCP or by surgery (open/laparoscopic). Mortality is nil but morbidity is more for open procedures.

Conclusions : The patient's age, underlying general conditions being the only standardizable factor with facilities for endoscopic, laparoscopic management, the CBD stone management varies from institution to institution and institution's resources. Depending on all these factors, there can be no definite algorithm for the management of CBD stones.

Keywords: CBD stones (CBDS), Radiology, Bilirubin, Surgery, laparoscopic common bile duct exploration (LCCBDE)

INTRODUCTION

Common bile duct stones (CBDS) are estimated to be present in 10-20% of individuals with symptomatic gallbladder which is also often associated with serious complications, including obstructive jaundice, acute suppurative cholangitis, and acute pancreatitis. Early diagnosis and prompt treatment is the most important for managing CBD stones.

Despite advances in surgery common bile duct stones (CBDS) is still a serious challenge to surgeon which is commonly performed in conjunction with cholecystectomy.

The incidence of CBDS in patients with symptomatic cholelithiasis varies widely in the literature between 5% and 33% according to age. CBDS are either primary (originating within the CBD) or secondary

(originating in the gallbladder) and pass into the CBD. It is recommended that patients diagnosed with common bile duct stones (CBDS) are offered stone extraction if possible. A variety of imaging modalities can be employed to identify the condition. Abdominal ultrasound and magnetic resonance cholangiopancreatography (MRCP) are the most common non-invasive pre-operative imaging modalities for detection of CBDS.

Common bile duct stones are present in approximately 5% of the patients undergoing elective cholecystectomy and 10% of patients with acute cholecystitis. No single blood test or combination of blood tests can predict whether a CBD stone is present. Intraoperative cholangiography is a gold standard for diagnosis. If CBD stones are diagnosed pre-operatively, several different treatment modalities can be utilized. The factors that determine the optimal approach include the patient's age and general condition. It is also important to consider the local expertise of the Surgeon and the endoscopist in managing CBD stones. Hence the algorithm for managing these patients will vary from one locale to another.

Management of confirmed cases of CBDS may involve Endoscopic Retrograde Cholangiopancreatography (ERCP), Surgery and radiological methods of stone extraction. Surgical techniques include open, laparoscopic common bile duct exploration (LCCBDE) or both.

Retained or recurrent CBD stones represent the most common indication for endoscopic sphincterotomy, and ERCP with sphincterotomy successfully treats 95% of these cases².

Laparoscopic duct exploration and ERCP are highly successful in removing CBDS. The use of biliary stent as sole treatment for CBDS should be restricted to a selected group of patients with limited life expectancy and/or prohibitive surgical risk.

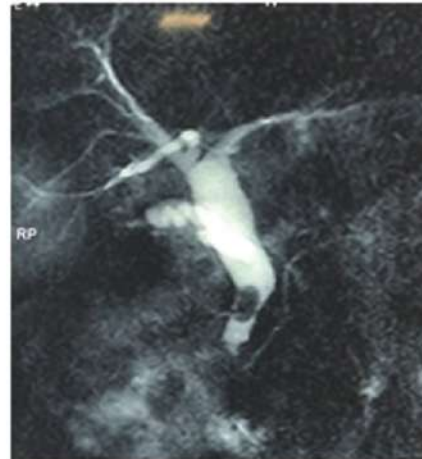


Fig. 1. Common bile duct stone (post cholecystectomy status)

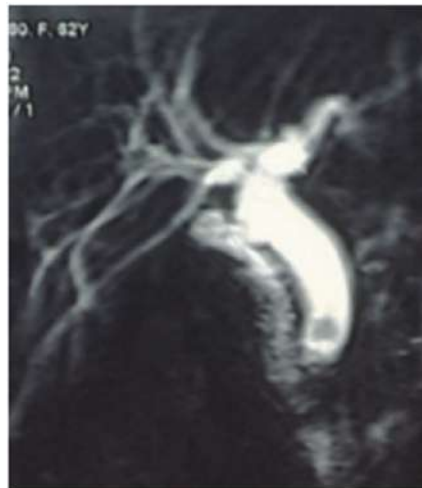

Fig. 2. Remnant gall bladder with CBD stones.

METHODS

The present study was carried out on patients retrospectively between January 2018 to December 2022, admitted in surgery Department of Down Town Hospital, Dispur, Assam. Diagnostic investigations including ultrasonography abdomen, LFT were done in all cases. MRCP was also selectively done. Procedural investigations like Hb%, coagulation profile, TLC, DLC, RBS, Blood urea, serum creatinine, chest Xray and ECG were performed in all cases.

Inclusion criteria

1. All the cases of common bile duct stones with the patient's age > 12 years.
2. Open CBD exploration.
3. Laparoscopic CBD exploration.

4. ERCP
5. Combination of the above methods.

Exclusion criteria

1. Exclusion criteria were patient age ≤ 12 years.
2. Those patients with CBD stones but not treated by any of the modalities due to – medical contraindication.

Choice of treatment modality was ERCP with \pm biliary stenting, Open CBD exploration with T-tube drainage/biliary stenting, Laparoscopic CBD exploration with T-tube drainage/biliary stenting. Some patients underwent failed ERCP followed by open CBD exploration due to impacted stone at the CBD. All patients received prophylactic antibiotics. All patients were screened for any coagulopathy and treated appropriately with vitamin K or fresh frozen plasma depending upon the severity and urgency of the procedure.

For open surgery with T-tube closure; discharge was done after the 5th day. Patients with biliary enteric anastomosis were discharged when they were taking oral diet, feeling symptomatically better and the suture wound had healed. Some patients with surgical site infection had extended stay till the surgical wound was dry and healing.

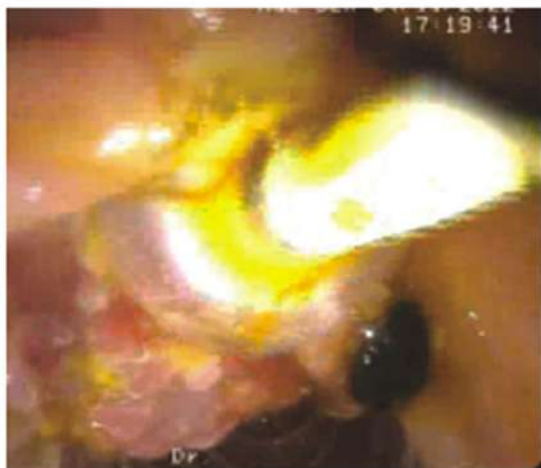

Figure – 3. ERCP CBD stone removal using balloon.

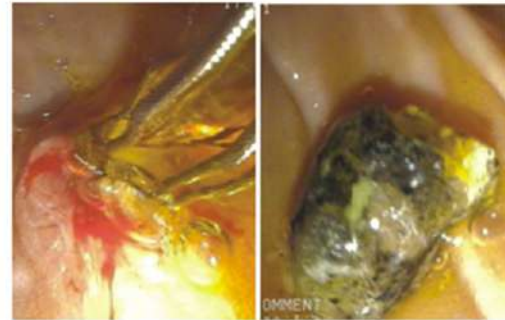


Figure – 4. ERCP CBD stone retrieval using Dormiabasket

For laparoscopic CBD explorations protocol similar open CBD was followed. Abdominal drains were used in all open and laparoscopic CBD exploration cases. It was kept in subhepatic space and removed when become dry in cases on t-tube insertion. All patients were followed up on outpatient basis with repeated assessment of patients’ symptomatic status, physical exam, liver function tests and abdominal ultrasonography.

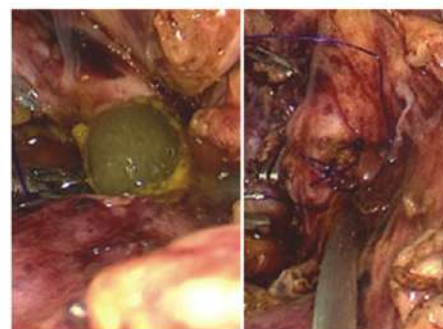
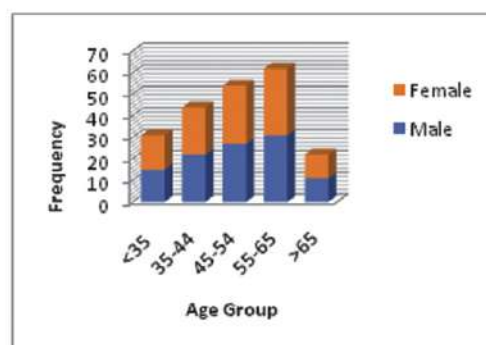


Figure- 5. Laparoscopic CBD exploration, stone removal, and T-tube placement

RESULTS

Age incidence

Age of the patients varied from 12 to 76 years. The mean age for males was 50.92 years and for female, it was 51.74 years.



Graph 1 :Sex Incidence

Out of the 213 patients, 77 (36.15%) were male and 136 (63.84%) were female.

Duration of hospital stay

Patients undergoing open CBD explorations stays 4-5 days in the hospital, Laparoscopic CBD exploration for 3 days & ERCP for 1-2 days.

Presenting symptoms

Patients presented with complaint of pain upper abdomen, nausea, vomiting, jaundice, passing high colored urine.

USG features

Some patients had undergone cholecystectomy and gall bladder were not visualized. Some patients had thickened/ contracted gall bladder suggestive of chronic calculous cholecystitis.

MRCP

MRCP was advised in some cases where USG shows difficult anatomy of the common bile duct. Due to financial constraint, not all the patients were advised for MRCP.

TREATMENT

ERCP

Out of 213 patients, 152 patients underwent ERCP with CBD clearance. These cases also include some patients with biliary stenting.

Open surgery

42 patients underwent open CBD exploration with choledocholithotomy with T-tube closure / biliary stenting. These cases also include some failed cases of ERCP.

Laparoscopic CBD exploration

18 cases had successful laparoscopic clearance of common bile duct stones with T-tube closure and 1 case with closure with biliary stent. Two cases were converted to open procedure following laparoscopic cholecystectomy.

Follow up

Follow up was done 7-10 days to 30 days following procedures. Mortality was nil in ERCP, open and invasive procedures. T-tube drainage / biliary stent was removed 21 days following surgery.

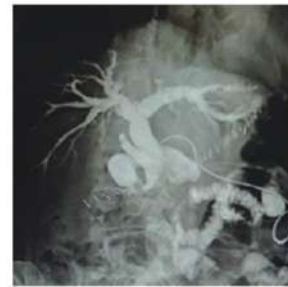

Figure -6. T-tube cholangiogram (Follow up)

DISCUSSION

It is estimated that common bile duct stones are present in anywhere from 1-15% of patients with cholelithiasis³. Common bile duct stones are present in approximately 5% of patients undergoing elective cholecystectomy and 10% of patients with acute cholecystitis. No single blood investigation or combination of blood investigations can predict whether a common bile duct stone is present.

Intraoperative cholangiography is the gold standard of diagnosis but CBD stone can be diagnosed preoperatively with ultrasound, ERCP, or MRCP. If choledocholithiasis is diagnosed preoperatively, several different modalities can be utilized.

The factor that determines the optimal approach include patient's age and condition, the presence of jaundice or cholangitis and size of the duct and stone. It is also important to consider the local expertise of the surgeon and endoscopist in managing common duct stones. Hence, algorithm for managing these patients will vary from one locale to another.

The natural history of choledocholithiasis is unpredictable. Small stones may pass spontaneously into the duodenum without causing symptoms, or they may obstruct the pancreatic duct temporarily, induce an episode of pancreatitis, and pass into the duodenum with relief of symptoms. Stones that do not pass into the duodenum may reside in the bile duct for long, symptom free periods, then suddenly precipitate an episode of jaundice or cholangitis.

According to Gerard, the overall incidence of CBD stones was 8% of the cases with cholelithiasis. The female to male ratio was 1.5. According to Wani et al, 94% had pain in the right upper abdomen. According to Acosta et al, gall stones are responsible for 50% of all cases of pancreatitis.

Clinical jaundice was present in some patients. This was roughly in accordance to meta-analysis by Abboud et al which showed jaundice having positive predictive value of 39% for choledocholithiasis. According to that study, the specificity of cholangitis in predicting CBD stones was 99%.

The abdominal USG was able to detect gall stones in gall bladder in all cases (100%) which agrees with Zinner et al which states that the presence of associated gall bladder stone can be confirmed >98% of patient with gall stones and dilation of the intra-hepatic biliary system can be identified in most.

The specificity of ERCP in confirming CBD stones was 100%, which compares with that of Frey et al of 98%. Sensitivity could not be determined as ERCP was only selectively used. All patients underwent ERCP with endoscopic sphincterotomy and stone extraction by either Dormia basket or Fogarty balloon.

The success of ERCP in clearing the CBD of stones was 140 out of 152 (92.1%), which agrees with Freeman et al, which states that complete clearance of all CBD stones is achieved endoscopically in 71-75% of the patients with the first procedure and 84-95% of the patients with multiple endoscopic procedures.

Approximately 30% of the patients will require intraoperative T-tube cholangiogram following cholecystectomy at the time CBD clearance. Cholangiography was accurate in 100% of the cases in our studies compared to Girard et al, of 88%. While mortality is nil in both open and minimally invasive procedures. Zero mortality in open CBD exploration, Pappas et al and endoscopic, Shivak, laparoscopic CBD Petelin, have been recorded which agrees with our study.

With the advent of new laparoscopic techniques and greater expertise of endoscopic procedures, the management of CBD stones has been subject to much debate during the past several years.

This study was undertaken to get a clinical perspective of CBD stones and to determine the optimal approach for the management with the age of the patient, general condition, complicating factors, availability of endoscopy and minimally invasive

procedure, determining the algorithm of treatment. The result of our study was focused on the development of management protocol in our institutional setting.

In conclusion, the patients' age, underlying general condition being the only standardizable factor with facilities for endoscopic, laparoscopic management, the CBD stone management varies from institution to institution and institution's resources. Depending on all these factors, there can be no definite algorithm for the management of CBD stones

CONCLUSION

REFERENCES

1. Park CH, The management of bile duct stones, Korean J Gastroenterol. 2018 May 25;71 (5)
2. Maingots operative surgery 12th ED, P- 47; Michael J. Zinner, MD, FACS, Stanley W. Ashley, MD, FACS.
3. Christopher F. McNicoll, Alyssa Pastorino, Umer Farooq, Mary J. Froehlich, Charles R. St Hill, Choledocholithiasis; Statpearls publishing 2023 Jan.
4. Jinfeng Z, Yin Y, Chi Z, Junye G. Management of impacted common bile duct stones during a laparoscopic procedure: a retrospective cohort study of 377 consecutive patients. Int J Surg. 2016; 32:1-5
5. Christopher Molvar, MD and Bryan Glaenger, MD; Choledocholithiasis: evaluation, treatment, outcome; Semin Intervent Radiol. 2016 Dec; 33(4): 268-276.
6. Tarantino G, Magistri P, Ballarin R, Assirati G, Cataldo AD, Benedetto FD. Surgery in biliary lithiasis: from the traditional "open" approach to laparoscopy and the "rendezvous" technique. Hepatobiliary Pancreat. Dis Int. 2017; 16:595-601.
7. 3. Hartery K, Lee CS, Doherty GA, Murray FE, Cullen G, Patchett SE. Covered self-expanding metal stents for the management of common bile duct stones. Gastrointest. Endosc. 2017; 85:181-6.

8. 4. Quaresima S, Balla A, Guerrieri M, Campagnacci R, Lezoche E, Paganini AM. A 23 years' experience with laparoscopic common bile duct exploration. *HPB*. 2017; 19:29-35. Kumar N. *Int Surg J*. 2020 Jul; 7(7):2289-2293 *International Surgery Journal | July 2020 | Vol 7 | Issue 7 Page 2293*
9. 5. Schwab B, Teitelbaum E, Barsuk JH, Soper NJ, Hungness ES. Single-stage laparoscopic management of choledocholithiasis: an analysis after implementation of a mastery learning resident curriculum. *Surgery*. 2018; 163:503-8.
10. 6. Rosenthal RJ, Rossi RL, Martin RF. Options and strategies for the management of choledocholithiasis. *World J Surg*. 1998; 22:1125- 32.
11. 7. Zhan X, Wang Y, Zhu J, Lin X. Laparoscopic choledocholithotomy with a novel articulating forceps. *Surg Innovation*. 2016;23(2):124-9.
12. 8. Hungness ES, Soper NJ. Management of common bile duct stones. *J Gastrointestinal Surg*. 2006;10(4): 612-9.
13. 9. Cameron JL. *Current surgical therapy* 8th ed. Philadelphia: Elsevier-Mosby; 2004: 403-404.
14. 10. Blumgart LH. *Surgery of the liver, biliary tract and pancreas* 4th ed. Philadelphia: Saunders-Elsevier; 2007.
15. 11. Girard RM. Stones in the common bile duct: surgical approaches. In Blumgart LH, Fong (eds). *Surgery of the liver and biliary tract* 3rd ed. Philadelphia: Saunders; 2000:737.
16. 12. Acosta JM, Ledesma CL. Gall stone migration as a cause of acute pancreatitis. *New Eng J Med*. 1974; 290:484-7.
17. 13. Abboud PA, Malet PF, Berlin JA. Predictor of common bile duct stone prior to cholecystectomy: a meta-analysis. *GastrointestEndosc*. 1996; 44:450-5.
18. 14. Zinner MJ. *Maingot's Abdominal operations* 10th ed. Stamford (CT): Appleton and Lange; 1997: 1739-1753.
19. 15. Frey CF, Burbige EJ, Meinke WB. Endoscopic retrograde cholangiopancreatography. *Am J Surg*. 1982; 144:109-14.
20. 16. Freeman M, Nelson D, Sherman S. Complication of Endoscopic biliary sphincterotomy. *N Eng J Med*. 1996; 335:909.
21. 17. Schein CJ, Gliedman ML. Choledochoduodenostomy as an adjunct to choledocholithotomy. *Surg Gynecol Obstet*. 1981; 152:797-804.
22. 18. Papas TN. 100 consecutive common duct exploration without mortality 1990. *Ann Surg*. 1990; 211(3):260-2.
23. 19. Sivak MV. Endoscopic management of bile duct stones. *Am J Surg*. 1989; 158:228-40.
24. 20. Petelin J. Laproscopic approach to common duct pathology. *Am J Surg*. 1993; 165:487. Cite this article as: Kumar N. Common bile duct stones: its different aspects of presentation and management. *Int Surg J* 2020; 7:2289-93.

Urological dual Pathology Managed Laparoscopically– A Series of 3 Cases.



Dr. Debangna Sarma

M. Ch (Urology)

Associate professor, dept. of urology and renal transplant, Gauhati Medical College Hospital

J Assoc Surg of Assam 2023;1 : 10-14

JASA

The Journal of Association of Surgeons of Assam
Volume 30, No. 1
June 2023 to October 2023

Introduction :

Dual urological pathology is a rare condition, and it is literally double the difficulty for the urologist to treat the disease in the same setting. We present a case series of three patients with additional pathology in each case who were successfully treated laparoscopically. In the initial situation, a left donor nephrectomy was planned for a patient which, upon evaluation, was found to have an incidental left adrenal mass. In the second case, the patient presented with an upper polar renal mass, pelvi-ureteric junction obstruction, and renal calculus in same kidney. In our third case, the patient had a left adrenal lipoma with pelviureteric junction obstruction. Our objective is to enlighten everyone on the laparoscopic management of various pathologies which can be managed in a single setting. In resource-constrained nations like India, performing dual surgery at the same time is a wise decision but technically challenging at the same time. Surgeon should be well experienced and trained in the laparoscopic surgery for these types of situations.

Case 1:

A 60-year-old male patient was referred to our department as a potential kidney donor. The evaluation of a routine CT renal angiography scan suggested the presence of an incidental well-defined fat density lesion (-70HU) measuring 11x9x13 mm in the left adrenal gland fig. According to biochemical analysis, serum cortisol levels were 4.86 (at 11 p.m.) and 0.99 (at 8:00 a.m.). The 24 hour urinary metanephrine level suggested 78.7mcg/day. After additional evaluation for donor nephrectomy, a laparoscopic left donor nephrectomy with adrenalectomy was performed. (fig 3 and Fig 4)

Intraoperatively, the adrenal gland was removed first, and no vasopressor support was required. The retrieved kidney was transplanted into the recipient after a thorough look for any remaining adrenal tissue (Fig 6). The patient was discharged on postoperative day 3 without incident.

The adrenal mass histopathology report was suggestive of myelolipoma. (Fig : 8)

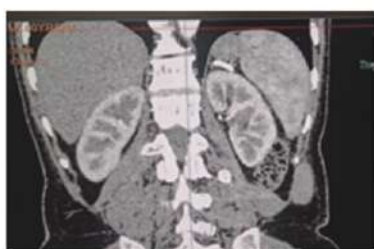

Fig: 1

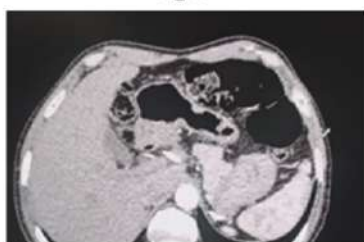


Fig: 2

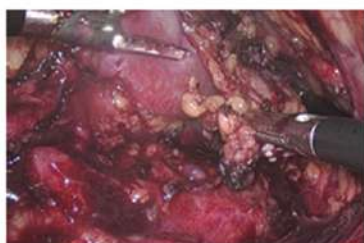


Fig: 3

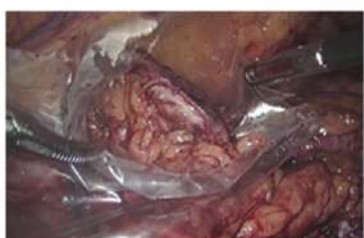

Fig: 4

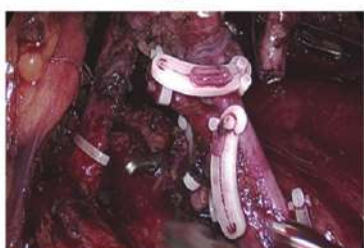

Fig: 5

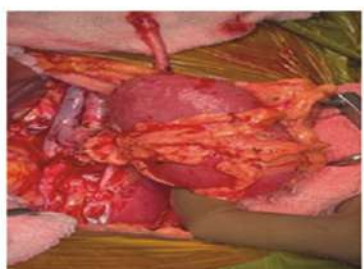

Fig: 6

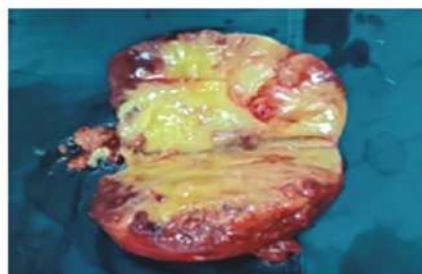


Fig: 7

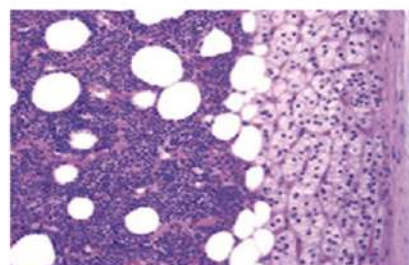


Fig: 8

Case 2:

A 50-year-old female patient presented to our department with two months of abdominal pain that was described as mild and profound. There was no history of weight loss or hematuria. The patient underwent ctivu, which was suggestive of a solid hypervascular lesion measuring approximately 20 x 16 mm in the upper polar region of the right kidney and involving the anterior cortical region. A portion of the mass was exophytic, and the surrounding lipid planes remained intact. It also revealed a hydronephrotic right kidney with disproportional dilatation of the renal pelvis and a constricted pelviureteric junction. A calculus measuring 13 x 12 mm and having a density of approximately 1570 HU was observed in the right renal pelvis. In the lower calyx of the right kidney, another calculus measuring 11 x 9 mm with a density value of approximately 1150 HU was identified as an additional finding. (fig 9 and fig 10)

In consideration of all these concomitant pathologies, a laparoscopic right partial nephrectomy, right pyelolithotomy, and right pyeloplasty with 6 frdj stenting was planned. The entire procedure was completed in 100 minutes, with WARM ischemia time limited to 30 minutes.(fig 11 – fig 15) The patient was discharged on post-operative day 4 with a DJ stent in place, which was removed after four weeks in accordance with our institution's protocol.

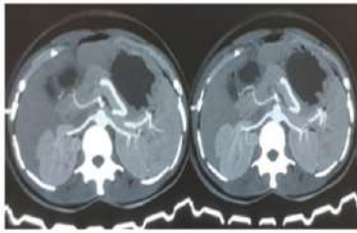


Fig: 9

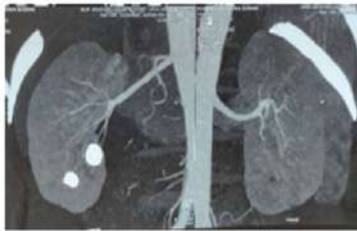

Fig: 10

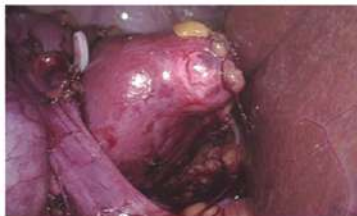

Fig: 11

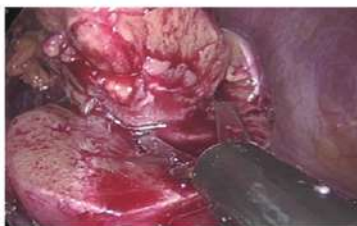

Fig: 12

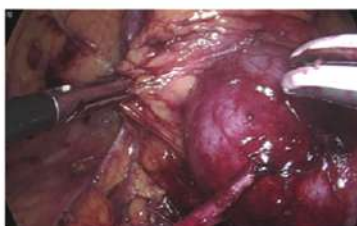

Fig: 13

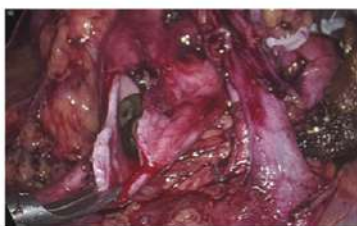

Fig: 14

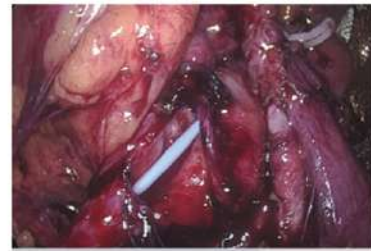


Fig: 15

Histopathological report was suggestive of clearcell carcinoma with clear surgical margins. (fig 16)

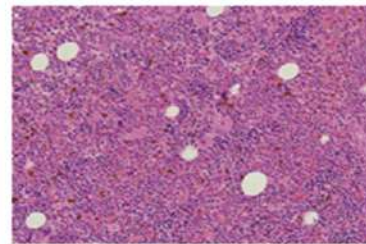


Fig: 16

CASE 3 :

A 50-year-old male patient presented with intermittent left flank pain that was dull, throbbing, and progressively increasing in intensity over past two years. The patient underwent an abdominal ultrasound that suggested left PUJ obstruction with hydronephrosis. The patient subsequently underwent a CT IVU, which suggested left PUJ obstruction. The patient also had a 23 mm x 22 mm left adrenal myelolipoma.(fig 17)

The patient also underwent an MRI of the abdomen, which suggested a well-defined lesion involving the left adrenal gland, suggestive of adrenal adenoma (25x22 mm), as well as evidence of left PUJ obstruction with hydronephrosis.

Laparoscopic left adrenalectomy and left Anderson Hynes pyeloplasty with 6F DJ stenting were performed .(fig 18 – 21) .The abdominal drain was removed on post-op day 3. The postoperative period was uneventful.Histopathological report was suggestive of adrenal myelolipoma.

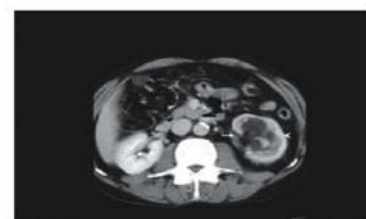

Fig: 17

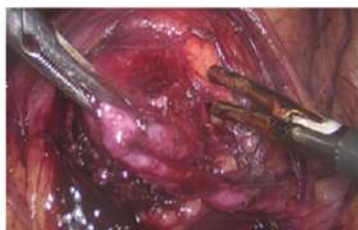

Fig: 18

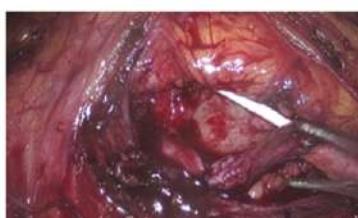


Fig: 19

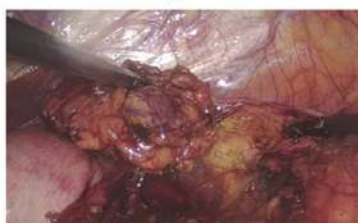

Fig: 20

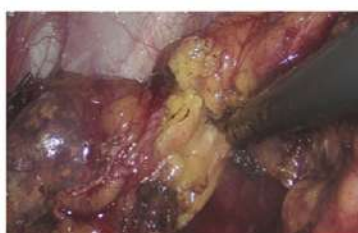

Fig: 21

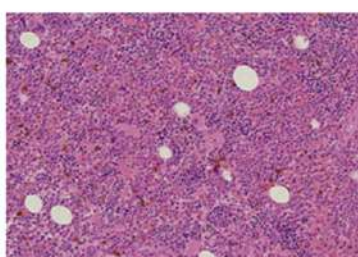


Fig: 22

Discussion-Adrenal myelolipomas are uncommon nonfunctional adrenal gland lesions. They are usually found incidentally [1]. Gierke first described myelolipoma in 1905 [2]. Previously, simultaneous laparoscopic surgery for two distinct pathologies has been reported. Renal transplantation is the most effective treatment for end-stage renal disease. The effect of carcinoma on transplanted graft is greater than that of the general population. It substantially

impacts a patient's existence by necessitating dialysis and decreasing their life expectancy. (5) It is expected to be possible to distinguish between benign lesions treatable conservatively and those requiring graft nephrectomy. (6) Pelvi-ureteric junction (PUJ) obstruction is a functional or anatomical obstruction to the passage of urine from the renal pelvis into the ureter at their anatomical junction caused by intrinsic or extrinsic forces. (7) It is frequently caused by congenital anomalies or stones. (8) Rarely, ureteral obstruction can occur if the tumour originates from the ureter or develops in close proximity to it. Very few cases of renal cell carcinoma with incidental PUJO have been documented. Likewise, PUJO with adrenal myelolipoma is a rare condition with very few reported cases.

Conclusion: With the advancement of cross-sectional imaging, there will be an increase in the number of patients diagnosed with multiple pathologies in the same kidney. In the era of minimal access surgery, both surgeons and patients are more inclined towards the laparoscopic surgeries. Consequently, a surgeon should be well-versed in anatomy as well as laparoscopic surgery to better meet requirements for minimal access surgery. With more experience, a surgeon can plan a procedure with minimal adverse effects and patient morbidity. The purpose of this paper is to persuade urologists to embrace and be trained in minimal access surgery while simultaneously minimising patient morbidity.

References :

- [1] M. Amendolara, C. Barbarino, D. Bucca, et al., "Giant and bilateral adrenal myelolipoma," *Il Giornale di Chirurgia*, vol. 29, no. 3, pp. 85–88, 2008.
- [2] E. Gierke, "Ueber Knochenmarksgewebe in der Nebenniere Beitr," *Journal of Pathologic Anatomy*, vol. 37, pp. 311–325, 1905.
- [3] Molmenti EP, Pinto PA, Montgomery RA, et al. Concomitant surgery with laparoscopic live donor nephrectomy. *AmJ Transplant* 2003;3:219–223.
- [4] Schwartz BF. Laparoscopic adrenalectomy with simultaneous management of renal pathology. *BJU Int* 2004;93:417–419.

(5) Acuna SA. Etiology of increased cancer incidence after solid organ transplantation. *Transplantation reviews (Orlando, Fla)*. 2018;32(4):218-24

(6) Bellini MI, Gopal JP, Hill P, Nicol D, Gibbons N. Urothelial carcinoma arising from the transplanted kidney: A single-center experience and literature review. *Clin Transplant*. 2019;33(6):13559.

(7) Kausik S, Segura JW. Surgical management of ureteropelvic junction obstruction in adults. *Int Braz J Urol* 2003;29:3-10.

(8) Tayib AM. Long term results of pyeloplasty in adults. *Saudi Med J* 2004;25:363-6.

(9) double trouble: pelvi-ureteric junction obstruction and renal cell carcinoma in right to left crossed fused ectopia. S. Saini, S. Yadav, B. Nayak: DOI:10.1136/bcr-2016-217496; Corpus ID: 25337130

**Authors:****Dr. Shardha Srinivas¹****Dr. K Bhuyan²**1. Junior Resident, Deptt of Surgery,
Gauhati Medical College Hospital2. Professor of Surgery, Gauhati
Medical College Hospital.

Correspondence:

Dr. K Bhuyan

kanakbhuyan@gmail.com.

J Assoc Surg of Assam 2023;1 : 15-19

JASAThe Journal of Association of
Surgeons of Assam
Volume 30, No. 1
June 2023 to October 2023**Abdominal wound Dehiscence : Predicting Factors and Evaluation of Management Strategies**

ABSTRACT : BACKGROUND : The wound dehiscence or wound failure is not uncommon post laparotomy. The impact of surgical wound dehiscence can considerably increase morbidity and mortality. There are local and systemic factors that can contribute to the occurrence of wound dehiscence. The aim of this study was to determine the incidence of abdominal wound dehiscence and its risk factors with an overview of management strategies.

MATERIALS AND METHODS: This prospective observational single centre hospital based was conducted in a tertiary care centre on one hundred consecutive Patients of either sex above the age of 18 years undergoing laparotomy. Demographic data, BMI, preoperative Haemoglobin, Albumin, associated co-morbidities, ASA classifications, duration of surgery, type of surgery (emergency, elective), closure technique with management strategies were taken as study tools. Data was analysed using Chi-square test of significance. Fischer's t test was used for comparison of parametric data. P value <0.05 was taken as significant.

RESULTS: The present study evaluates 100 consecutive laparotomy cases of 62 emergency and 38 elective cases. Sixteen patients (16%) patients had abdominal wound dehiscence post laparotomy. The BMI of 10 patients (62.5%) was >30 and 6 patients had BMI <30 (37.5%). p value was found to be 0.0202. The haemoglobin level was Hb <10 g% in 11 patients (68.75%) and 5 patients had Hb >10 g% (31.25%) (table 1) with p value of 0.0008. Ten patients (25%) had hypoalbuminemia <2.5gm/dl. The p value was found to be of 0.0432. Six patients (37.5%) of interrupted closure group and 10 (62.5%) patients of continuous suture group developed wound dehiscence. The p value was 0.7865. Wound dehiscence developed in 12 (75%) patients in the emergency group followed by 4 (25%) in elective group. The p value was 0.7865 with relative risk of 0.22.

Conclusions: Emergency surgery. Male gender, old age, anaemia, hypoalbuminemia, post operative wound infection, are strong predictive factors of abdominal wound dehiscence.

Comorbidities like diabetes mellitus, obesity also increases the risk of wound failure. Prolonged duration of surgery and continuous technique of abdominal wound closure increase incidence of wound failure.

Keywords: Anaemia-hypoproteinaemia-emergency surgery-wound dehiscence

Introduction: The incidence of post laparotomy wound dehiscence occurs in 0.25% to 3% of patients 1,2. However, in India the incidence may reach up to 10–30% 3,4. The impact of surgical wound dehiscence can considerably increase morbidity and mortality, prolong hospital stay, delays adjuvant treatment, cause suboptimal aesthetic outcome and impair psychosocial wellbeing. There are local and systemic factors that can contribute to the occurrence of wound dehiscence. It is crucial to determine the risk factors in order to avoid it and to have a better post operative wound result. The present study aimed to determine the incidence of abdominal wound dehiscence and its risk factors with an overview of management strategies.

MATERIALS AND METHODS : This prospective observational single centre hospital-based study was conducted in the Department of General Surgery, Gauhati Medical College and Hospital, Guwahati during June' 2020 to May'21 on one hundred consecutive Patients of either sex above the age of 18 years undergoing laparotomy for both elective and emergency. Patients with previous laparotomy and obstetrics and gynaecological surgery were excluded. Demographic data, detailed history of the patient including BMI, preoperative Haemoglobin, Albumin, associated co-morbidities, ASA classifications, duration of surgery, type of surgery (emergency, elective), closure technique with management strategies of Conservative, Secondary closure, Secondary closure with retention suture, Debridement and delayed secondary closure were taken as study tools. Data was analysed using Chi-square test of significance. Fischer's t test was used for comparison of parametric data. . P value <0.05 was taken as significant. Informed and written consent from participants were taken during the study with approval from institutional ethics committee.

Results and Observations: The present study evaluates 100 consecutive laparotomy cases of 62 emergency and 38 elective cases. Sixteen patients (16%) patients had abdominal wound dehiscence post laparotomy (Table 1). The majority of wound dehiscence patients belonged to the age group of 41-50 years (mean 48.6), youngest patient was 25 years and oldest patient was 70 years. There were 12(75%) male and 4(25%) female patients with of male and female ratio of 3: 1.

In the present study, out of 16 cases of wound dehiscence The BMI of 10 patients (62.5%) was >30 and 6 patients had BMI <30 (37.5%). p value was found to be 0.0202 with relative risk of 0.32. The haemoglobin level was Hb <10 g% in 11 patients (68.75%) and 5 patients had Hb >10 g% (31.25%) (table 1) with highly significant p value of 0.0008. The serum albumin level was less than 2.5 gm/dl in 39 patients in the study group and in 10 patients (25%) developed wound dehiscence. The p value was 0.0432 with relative risk of 2.61. In the study group 35 patients had a preoperative fasting blood sugar more than 127 g/dl, seven (43.8%) of these patients developed wound failure postoperatively with p value of 0.5682 and relative risk of 0.6. Out of 100 cases who underwent laparotomies, 39 patients had serum albumin less than 2.5 g/dl. Ten patients (25%) of 39 patients with hypoalbuminemia developed wound dehiscence. The p value was found to be of 0.0432 with relative risk is of 2.61.

The Abdominal wall was closed with interrupted technique in 42 patients and in the other 58 patients with continuous technique. Six patients (37.5%) of interrupted suture group and 10(62.5%) patients of continuous suture group developed wound dehiscence. The p value was 0.7865 with relative risk of 0.22. In the study population 62 patients underwent emergency surgery followed by 38 patients with elective surgery. Wound dehiscence developed in 12(75%) patients in the emergency group followed by 4(25%) in elective group. The p value was 0.7865 with relative risk of 0.22. Ten patients (62.5%) of the wound dehiscence cases had either contaminated or dirty wounds. 6 (37.5%) patients with wound dehiscence had clean contaminated wounds.

No patients with clean wound developed wound dehiscence. In the present study, wound dehiscence developed in 12 patients (75%) who had undergone surgery lasting more than 120 minutes. In cases where the duration for surgery was less than 120 minutes, 4 patients (25%) developed wound dehiscence.

Table 1: Demographic and risk factors on wound failure

Particulars of study	Descriptions	Nos of Patients (%)	P-value
Age	<40	4(25)	
	>40	12(75)	
Sex	M	12(75)	
	F	4(25)	
BMI	<30	6(37.5)	0.02
	>30	10(62.5)	
Hb%	>10gm%	11((68.7)	0.0008
	<10gm%	5(31.5)	
Albumin	<2.5gm	10(62.5)	0.04
	>2.5gm	6(37.5)	
Co-morbidities	Blood Sugar >127gm/dl	7(43.8)	0.56
ASA Grade	Gr I	10(62.5)	
	Gr II	4(25)	
	GrIII	2(2.5)	
Surgical procedure	Elective	12(75)	0.278
	Emergency	4(24)	
Duration of Surgery	<120min	12(75)	0.004
	>120mins	4(25)	
Closure technique	Continuous	10(62.5)	0.786
	Interrupted.	6(37.5)	

Table 2: Management of wound dehiscence:

Technique of management	Mean duration of stay (days)
Conservative management (by secondary intention)	30.25±3.1
Secondary suturing	19.83±2.62
Delayed secondary suturing (debridement and secondary suturing)	28±2.94
Secondary suturing with retention sutures	18.5±4.94

The mean duration of hospital stay in patients with wound dehiscence was 24.31±5.75 days. The duration of hospital stay was longest for patients managed by means of conservative management (Table 2). **Discussion:** This study reviewed a total of 16 patients with wound dehiscence in a population of 100 consecutive patients admitted undergoing laparotomies both in emergency and elective setup. The incidence of wound dehiscence in the present study is 16%. This study is similar

to that of another study⁴. The age wise distribution in this study showed that the majority of patients belonged to the 4th and the 5th decade group with mean age of the affected patients being 48.12 years. This finding is similar to that of some other studies^{5,6,7,8}. The sex distribution as found in this study was that of male preponderance with 12 out of 16 cases being male (75%) and 4 cases being female (25%). The male to female ratio of the study is 3:1. This finding was in concordance with most of the studies^{3,9}. The Obesity (BMI>30) was seen in 62.5% cases of wound dehiscence in this study. This can be because of decreased blood circulation in the fatty tissue resulting in poor wound healing. Obesity is also associated with other co-morbid conditions like diabetes, hypertension which also causes poor wound healing. The present study is in correlation with similar one 4. In the present study, anaemia (Hb <10 g/dl) was observed in 11 out of 16 cases of wound dehiscence (68.75%). In the present study anaemia is a significant factor responsible for wound dehiscence as the p value is 0.008. This finding is similar to other study^{4,5,4,8}. Incidence of hypoalbuminemia (serum albumin <2.5g/dl) in abdominal wound dehiscence in the present study was 62.5% with p value of 0.0432. This observation was similar to similar other study^{4,8,10}. High blood sugar level was found in 7 out of 16 cases of wound dehiscence (43.75%) was with significant p value of 0.56. This study was similar to other study^{4,6}. In this study 10 (62.5%) patients with dehiscence had either contaminated/dirty wound. Wound contamination and wound infection remain a foremost important factor for wound dehiscence and an important aetiology of wound failure^{3,11,12}. Local sepsis is the single most important factor delaying collagen synthesis and increasing collagen lysis resulting in development of wound failure⁴. In the present study, patients were evaluated on the basis of duration of surgery lasting more than 120 minutes or less. Out of 16 patients with wound dehiscence, 16 (75%) had laparotomy lasting for more than 120 minutes while the rest 4 patients (25%) had surgery lasting less than 120 minutes. The p value was 0.0041 which was found to be statistically

significant^{13,14,15}. The current study found 12 patients out of 16 (75%) had emergency laparotomies which developed wound dehiscence. This was similar to other studies^{16,17,18,19}. In the current study, out of 16 patients that developed wound dehiscence, 6 (37.5%) cases underwent interrupted closure and the rest 10 (62.5%) cases underwent continuous suturing with polydioxanone loop. The incidence of wound dehiscence was greater in the continuous group when compared to the interrupted group^{20,21,22}.

Conclusions : Abdominal wound dehiscence is common following emergency surgery. Male gender, old age, anaemia, hypoalbuminemia, post operative wound infection, are strong predictive factors of abdominal wound dehiscence. Comorbidities like diabetes mellitus, obesity also increases the risk of wound failure. Prolonged duration of surgery and continuous technique of abdominal wound closure accounted for increased incidence of wound failure.

References:

- 1) Gislason H, Gronbech JE, Soreide O. Burst abdomen and incisional hernia after major gastrointestinal operations: comparison of three closure techniques. *Eur J Surg* 1995; 161:349–354.
- 2) Haddad V, Macon WL 4th. Abdominal wound dehiscence and evisceration: contributing factors and improved mortality. *Am Surg* 1980; 46:508–513.
- 3) Waqar SH, Malik ZI, Razzaq A, M T Abdullah, A Sharma, MA Zahid- Frequency and risk factors for wound dehiscence/burst abdomen in midline laparotomies. *J Ayub Medical College Abbottabad* 2005; 17(4)
- 4) Hegazy T, Soliman S. Abdominal wall dehiscence in emergency midline laparotomy: incidence and risk factors. *Egypt J Surg.* 2020;39(2):489.
- 5) Nagamuneiah, Roopashri Kumar NM, Saritha P, Prakash GV. Abdominal Wound Dehiscence - A look into the risk factors. *Journal Of Dental & Medical sciences.* Vol -14, Issue-10, Ver 1(oct 2015), 47-54

- 6) Mahey R, Ghetla S, Rajpurohitj, Desai D, Suryawanshi S: a prospective study of risk factors for abdominal wound dehiscence. *International surgery journal*. Jen 2017. Vol 4, Issue-1;1-5
- 7) Alizadeh Otaghvar H, Afsordeh K, Hosseini M, Mazhari N, Dousti M. Causes of wound dehiscence in trauma patients with penetrating and non-penetrating abdominal wound in Rasool Akram Hospital within 2017-2020. *J Surg Trauma*. 2020; 8 (4) : 156-160
- 8) Kapoor, K., & Hassan, M. (2016). A clinical study of abdominal wound dehiscence with emphasis on surgical management in Bangalore medical college and research institute, Karnataka, India. *International Surgery Journal*, 4(1), 134-140.
- 9) Aziz A, Alam S N, Shaikh I, Manzar S. Abdominal Wound dehiscence: An ongoing dilemma. *Pakistan Journal of Surgery*. Vol 25, Issue 3, 209. 284-8
- 10) Makela JT, Kiviniemi H, Juvonem T: Factors Influencing Wound Healing After Midline Laparotomy, *Annual Surg* 1995; 170 :387-9
- 11) Col C, Soran A, Col M. Can Post Abdominal Wound dehiscence be predicted? *Tokai J Exp Clin Med* 1998;23(3) :123-7.
- 12) Meena K, Ali S, Chawla A S, Aggarwal L, Suhani S, Kunmae S, Khan R N. A Prospective Study of Study factors influencing Wound Dehiscence After Midline Laparotomy. *Surgical Science*, 2013,4,354-8
- 13) Garg R, Shah S, Singh S, Singh B. A Prospective Study of Predictors for Post Laparotomy Abdominal Wound dehiscence. *Journal of Clinical & diagnostic Research*. 2014. Jan, Vol-8(1):80-83
- 14) Haley RW, Culver DH, Morgan WM, Identifying patients at high risk of Surgical Wound Infection. *Epidemiol*, 1985;12
- 15) Salman A, Ali A A, Karim F, Aslam N, Gondal K M, Chaudhury A M. Duration of surgery. Does it contribute to post operative wound infection? *Pak Journ Surg* 2001; 17(3):35-40
- 16) Van Ramshorst GH, Nieuwenhuizen J, Hop WC, Ardens C, Boom J, Jeekel J. Abdominal wound dehiscence in adults: development and validation of a risk model. *World of Surg*. 2010 jan; 34(1) :20-7
- 17) Khandra H, Vyas P H, Patel N J, Mathew J G. Factors Affecting Post Op Laparotomy Wound Complications. *International Archives of Integrated Medicine*. Vol-2, Issue-1, January 2015. 71-5
- 18) Mukhtiar Ali, Saeeda, Muhammad Israr, Hafiz Niamatullah: Frequency of abdominal wound dehiscence and role of wound infection as a major causative factor *Pak J Surg* 2014; 30(1):4-8
- 19) Graham DJ, Stevenson J T, Mchenry C R. The association of intra-abdominal infection and abdominal wound dehiscence. *Anu Surg* 1998;64(7):660-5
- 20) Fagniez P L, Hay J M, Lacàine F, Thomsen C. Abdominal midline incision closure. A multicentric randomized prospective trial of 3,135 patients, comparing continuous vs interrupted polyglycolic acid sutures. *Arch Surg*. 1985 Dec; 120(12):1351-3.
- 21) Agrawal C S, Tiwari P, Mishra S, Rao A, Hadke N S, Adhikari S, Srivastava A. Interrupted abdominal closure prevents burst: randomized controlled trial comparing interrupted-x and conventional continuous closures in surgical and gynecological patients. *Indian J Surg*. 2014 Aug;76(4):270-6.
- 22) Roy, A., Mukhopadhyay, M. & Rahman, Q.M. Abdominal closure with interrupted 'X' sutures prevent burst abdomen better when compared with continuous mass closure: A randomised trial in patients with perforative peritonitis. *Hellenic J Surg* (2016); 88, 405–409.



Dr. Manoj Saha

Department of pediatric Surgery
Nemcare Hospital, Guwahati

J Assoc Surg of Assam 2023;1 : 20-30

JASA

The Journal of Association of
Surgeons of Assam
Volume 30, No. 1
June 2023 to October 2023

Approaches to Few Common Paediatric Surgical Conditions : General Surgeon's Perspectives

Number of patients and pediatric surgeon ratio is far from expected in India and our part of the country in particular. Therefore, it is customary for the General Surgeons and pediatrician to be accustomed with common pediatric surgical conditions which in particular may have some detrimental effect if not dealt properly in appropriate time. Few amongst these are: pediatric hernia and hydrocele, appendicitis in children, undescended testis, acute scrotum- testicular torsion in particular and gall stone diseases in children.

Inguinal hernia and hydrocele

Introduction: Inguinal hernia and hydrocele share a common etiology. The surgical correction is also similar. Inguinal hernia (indirect) is a protrusion of intra-abdominal content into the inguino-scrotal/labial canal formed by failure of obliteration of the processus vaginalis. Hydrocele is the accumulation of fluid within the same spatial remnant.

Definition and nature of inguinal hernia and hydrocele:

During fetal life, the descent of testis into the inguinal canal and scrotum brings a small pouch of peritoneum alongside. This peritoneal extension is the processus vaginalis. In female, the formation of the labia has the same peritoneal remnant referred to as the "canal of Nuck". The peritoneal canal is obliterated in up to 95-98% of the fetuses before birth. Failure of this peritoneal fusion results in a spectrum of abnormalities. The degree of fusion failure results in either a hydrocele (fluid collection within the scrotum or along the cord) or a hernia (descent of visceral content into the groin or scrotum/labia).

Indirect inguinal hernia is the most common type of hernia in children. Inguinal hernia occurs 9 times more commonly in boys than in girls. Majority occurring on the right side (60%), 25% occur on the left side and 15% are bilateral. Bilateral occurrence may be synchronous or metachronous.

Diagnosis and workup

Inguinal hernia : Patients are initially assessed by history and clinical examination. History often reveals a sudden, intermittent appearance of a bulge in the groin during nappy change or when drying

after bathing. This usually is seen during straining or crying. The infant or child may appear in discomfort at such times. The child may develop an irregular bowel habit. In case of incarceration with obstruction, the child may vomit and develop abdominal distension. Clinical examination may be normal when the hernial sac is empty. If the hernia is incarcerated at the time of examination, a fixed mass is usually felt within the groin. An inability to palpate the upper limit of the mass is suggestive of herniation of visceral content from within the peritoneal cavity (Fig.1).

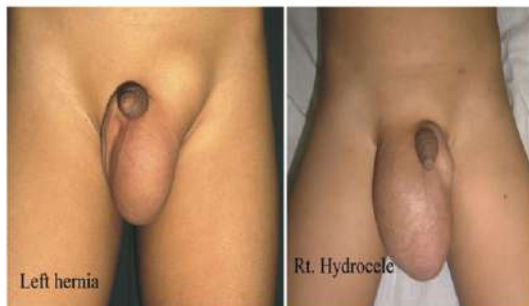

Figure 1: Male patients with left hernia and right hydrocele. Note a hernia is inguinoscrotal, whereas the hydrocele is confined to scrotum.

In female, a small mobile mass often appear in the groin or labia, which usually represents an ovary (Fig.2).

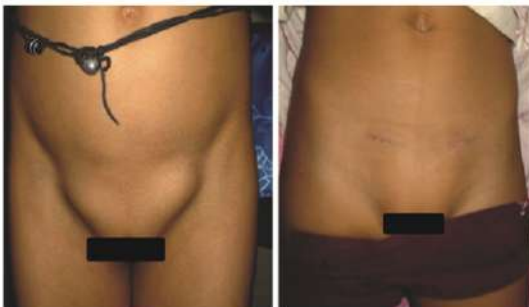

Figure 2: Female patient with B/L inguinal hernia (pre and post op).

The risk of hernia becoming incarcerated is highest during infancy. If not successfully reduced, incarceration can lead to obstruction and necrosis. Such patients may present with acute bowel obstruction and require resuscitation and emergency operation. Premature infants have an incarceration risk of up to 30% and it is halved in older children [1,2]. Persistent pressure on the delicate cord structures can lead to testicular vessel compromise and testicular

infarction [3]. Ovarian infarction may also occur but is very rare. Author had encountered one such case in a 2 months old girl (Fig.3).

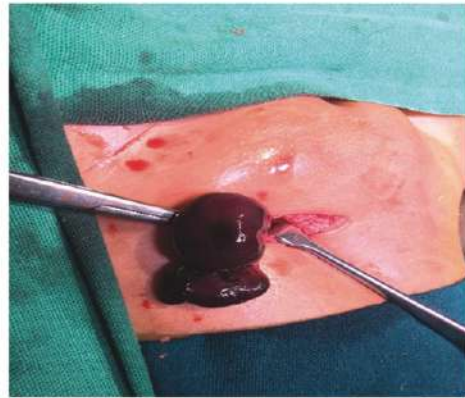


Figure 3: Two months old female baby with obstructed left inguinal hernia with ovarian torsion and gangrene inside hernia sac.

Hydrocele: History and clinical examination is important in differentiating hydrocele from hernia. Parents often describe a painless swelling within the scrotum appearing larger in the evening than in the morning or following a viral infection. Examination reveals a fluctuant painless swelling, which may or may not be reducible. Transillumination reveals a bright scrotum. But one must remember that a hernia in small infant may be transilluminant and must be differentiated clinically. Palpation above the swelling is usually possible, except in a large inguinoscrotal hydrocele.

Investigations:

The diagnosis for both inguinal hernia and hydrocele is usually clinical. Many a times parents give history of a groin swelling which strongly suggests a hernia but clinical examination fails to demonstrate it. In such cases photography by the parents at the time of appearance of the swelling may provide valuable clue for the diagnosis. In older children with indeterminate symptoms, ultrasound may play a role [4]. Others have also advocated the use of USG in detecting contralateral PPV prior to surgery in children.

Indications for surgery:

Inguinal hernia: There is no place in children for conservative management of inguinal hernia. Surgery is indicated for all pediatric patients where diagnosis of inguinal hernia is made. Premature infants with

hernia are usually operated upon prior to leaving the NICU [5]. Infants below 3 months should be operated on priority basis and older children with few symptoms may be operated electively.

Risk/Benefit: Risks of not operating an inguinal hernia include bowel incarceration/necrosis, as well as possible testicular/ ovarian compromise/necrosis [1,2,6,7]. In female torsion of the ovary is also possible. Short term complications of surgery include wound infection, injury to the vas and testicular vessels, as well as injury to the genito-femoral nerve, resulting in chronic pain. Reoccurrence of hernia is both a short and long term observation and is between 1% and 2%, though it is higher in premature infants. Recurrence rate is higher when operated in emergency situation. Testicular ascent following inguinal tissue contracture is another possible long term problem.

Hydrocele: Hydrocele in infancy, however, is associated with a spontaneous resolution of up to 2 years of age. But an encysted hydrocele and hydrocele appearing beyond infancy may not resolve. A conservative approach is often adopted primarily. Surgery for congenital hydrocele is usually offered after the age of 2 years for persistent fluid collection and possible risk of hernia later in life.

Risk/Benefit: Risks of non-operative management in hydrocele include persistent scrotal enlargement and potential hernia formation. Hydrocele is often considered a benign condition, though a large hydrocele may affect testicular morphology (flattening or elongation), if left untreated. In adults, hydrocele can be associated with an arrest of spermatogenesis [8].

Treatment and options:

When the hernia is incarcerated, an attempt at reduction should be made. Reduction should be tried by a trained physician, using analgesia and or sedation. Reduction may spontaneously occur prior to a manual attempt, if the infant's buttocks are elevated slightly to assist in the reduction of hernia contents. If the hernia remains incarcerated an operation is indicated. For those with incarcerated hernia, the risk of re-incarceration is reported to be as high as 15%, if surgery is delayed for more than 5 days.

Operative approach to inguinal hernia: Open herniotomy is the standard method of treatment

for pediatric hernias. Laparoscopic repair has emerged recently as an alternative technique.

Open technique of inguinal hernia repair: An inguinal crease incision is made on the side of the hernia. The procedure involves the separation of the hernial sac from the cord structures or round ligament (female). The sac is ligated at the neck and the distal sac is divided and excised.

Laparoscopic repair: In the recent years laparoscopic hernia repair is routinely performed in many centers and its efficacy and safety are well documented [9,10,11,12]. Basic principle is to encircle the internal inguinal ring and close it by a non-absorbable suture under laparoscopic control. This can be achieved either by intracorporeal suturing or by percutaneous extraperitoneal approach through a needle hole (Fig.4). Advantages of laparoscopic repair include excellent visual exposure, ready evaluation of the contralateral side, minimum dissection, and superior cosmesis. In addition there is decreased chance of injury to vas and vessels and iatrogenic ascent of the testis and decreased operating time especially in obese child.

The likelihood of patients with unilateral hernia, developing a contralateral hernia is between 8 and 15% [13]. Laparoscopic evaluation via hernioscopy/umbilical laparoscopy detects PPV in up to 30-50% of the patients [9,14]. If contralateral hernia/PPV is detected during surgery it can be treated at the same time. The recurrence rate following laparoscopic repair may be higher when compared with open repair. This may be related to surgical experience.

Operative approach for hydrocele: The surgical procedure is similar to that of open inguinal hernia repair. Once the PPV is ligated the distal sac must be evacuated by some means to eliminate the scrotal swelling. Therefore, laparoscopy has little role in hydrocele repair.

Expected post-treatment course:

Following surgery for inguinal hernia and hydrocele in children, patients are expected to be free from hernia and scrotal swelling. The post operative course for both open and laparoscopic repair appears to be similar. Though this surgery can be accomplished on out-patient basis, we prefer overnight hospital stay as most of the patients come from distance and parental intelligence for taking

care of a post operative child is not assured. Patients are expected to resume normal activity within 48 hours following surgery.

References:

1. Melone JH, Schwartz MZ, Tyson KR et al. Outpatient inguinal herniorrhaphy in premature infants: is it safe ? J Pediatr Surg 1992;27:203-237.
2. Mishra D. Inguinal hernia in premature babies: wait or operate ? Acta Pediatr 2001;90:370-371.
3. Kriger NR, Shochat SJ, McGowan V et al. Early hernia repair in premature infants: long term follow up. J Pediatr Surg 1994;29: 978-981.
4. Hata S, Takahashi Y, Nakamura T et al. Preoperative sonographic evaluation is a useful method of detecting contralateral patent processus vaginalis in pediatric patients unilateral inguinal hernia. J Pediatr Surg 2004;39:1396-99.
5. Boley SJ, Cahn D, Lauer T et al. The irreducible ovary: a true emergency. pediatr Surg 1991;26:1035
6. Syllianos S, Jacir NN, Harris H. Incarceration of inguinal hernia for infants prior to elective repair. J Pediatr Surg 1993;28:582-83.
7. Phelps S, Agarwal M. Morbidity after neonatal inguinal herniotomy. J Pediatr Surg 1997;32:445-47
8. Dandapat MC, Padhi NC and Patra AC. Effect of hydrocele on testis and spermatogenesis. Br J Surg 1990;77:1293
9. Schier F. Laparoscopic inguinal hernia repair—a prospective personal series of 542 children. J Pediatr Surg 2006;41:1081-1084
10. Shalaby R Y, Fawy M, Soliman S M, and Dorgham A. A new simplified technique for needlescopic inguinal herniorrhaphy in children. J Pediatr Surg 2006;41:863-867
11. Tam Y H, Lee K M, Sihoe J D Y et al. Laparoscopic hernia repair in children by the hook method. A single-center series of 433 consecutive patients. J Pediatr Surg 2009; 44(8):1502-1505
12. Shalaby R, Ismail M, Durham A et al. Laparoscopic hernia repair in infancy and childhood: evaluation of 2 different techniques. J Pediatr Surg 2010; 45 (11): 2210–2216
13. Lau S, Lee Y, Caty M. Current management of hernias and hydroceles. Semin Pediatr Surg 2007;16:50-57
14. Chan KL, Hui WC, Tam PK. Prospective, randomized single-centre, single-blind comparison of laparoscopic versus open repair of pediatric inguinal hernia. Surg Endosc 2005;19:927-32

Appendicitis in children

Introduction: Acute appendicitis is the most common intra-abdominal surgical condition in children, especially in adolescent teens. Although the condition is relatively uncommon during infancy and early childhood, there is disproportionately higher incidence of complicated appendicitis in this group due to difficulties in establishing an early diagnosis. In the United States, about 7% - 8% of the general population develops acute appendicitis and requires surgical intervention at some point of their lifetime [1]. Appendicitis is less frequent in third world countries mainly because of high dietary fiber intake but in urban areas its incidence is increasing due adoption of western lifestyles. Appendicitis remains an enigma- a simple disease that, despite our best effort remains the most commonly misdiagnosed surgical emergency. In fact, exclusion of the possibility of appendicitis is much more difficult than its diagnosis. Although, the diagnosis and treatment have improved, appendicitis continues to cause significant morbidity and still remains, although rarely, a cause of death.

Pathology: Appendicitis results from luminal obstruction followed by infection. The cause of obstruction is not always clear. inspissated and sometimes calcified fecal matter, known as fecalith, often plays a role. Fecaliths can be surgically found in approximately 20% of the cases of acute appendicitis and are reported in 30% to 40% of children with perforated appendicitis. Hyperplasia of appendiceal lymphoid follicles frequently cause luminal obstruction, as can parasitic infestations by Entameba, Strongyloides, Enterbius vermicularis, schistosoma, or, Ascaris species. Obstruction causes distension of the appendix and this initiates the pain which is vague and not localized. The obstructed appendix is a perfect breeding ground for trapped bacteria. As luminal pressure increases, lymphatic drainage is inhibited, leading to further edema and swelling. Finally, the increase in pressure causes venous obstruction, which leads to tissue ischemia, infarction, and gangrene. When the inflamed serosa of the appendix touches the parietal peritoneum, somatic pain fibers are triggered and the pain localizes over the appendiceal site, typically in the right lower quadrant. Further breakdown of the appendiceal wall leads to perforation with spillage of infected intraluminal contents with localizes abscess formation or generalized peritonitis (Fig.4).

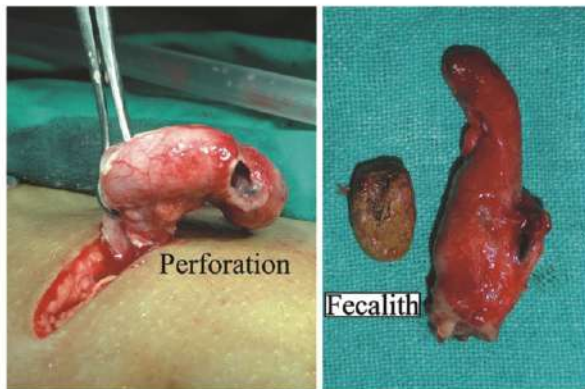

Figure 4: Acute appendicitis with perforation and fecalith.

Many terms have been used to describe different stages of appendicitis but these are vague and are of limited practical value, and only the distinction of perforated versus non-perforated appendicitis is clinically relevant. Because gangrenous appendicitis represents dead tissue and functionally acts as a perforation, it should be treated as perforated appendicitis.

Appendicitis is a continuum from simple inflammation to perforation over a period of 2-3 days, with perforation typically occurring after 24 – 36 hours of symptoms [2, 3]. Signs of perforated appendicitis include a temperature higher than 38.6 °C, leukocyte count greater than 14,000, and the presence of more generalized peritoneal signs.

Whether chronic or recurrent appendicitis exist has been debated for decades. Recent literature contends that they do exist and should be considered in the differential diagnosis of recurrent lower abdominal pain [4, 5].

Diagnosis : Diagnosis of appendicitis is mainly clinical and technologic advances in the diagnostic method are not foolproof. Pain is invariably present and is nearly always the first symptom. With retrocecal or pelvic appendix, the somatic pain is often delayed in onset and not localized in right lower quadrant because of the inflamed appendix not contacting the parietal peritoneum readily. Pain of a retrocecal appendix may be in the flank or back. Anorexia, nausea, and vomiting typically follow the onset of pain within a few hours. The appearance of these symptoms before the onset of pain casts doubt on the diagnosis. Anorexia is a helpful sign,

particularly in children, because a hungry child rarely has appendicitis. Diarrhea occurs more frequently in children than in adults, and can result in misdiagnosis of gastroenteritis.

Children with appendicitis usually do not scream and lay in the bed quietly. Localized tenderness is essential for diagnosis and is noted either on deep palpation or percussion. Tenderness can be mild or even masked by generalized pain in the initial stage. In retrocecal appendicitis the tenderness may be elicited posteriorly and pelvic appendicitis produces rectal tenderness. Perforation and peritonitis, initially is reflected as localized muscular rigidity and rapidly progresses to involuntary guarding and generalized rigidity of the abdomen. Routine rectal examination is of little benefit in the diagnosis; pain during rectal examination is present in 50% of the patients without appendicitis and absent in 50% of the patients with appendicitis. But it is of value when a pelvic appendix or abscess is suspected or when uterine or adnexal pathology is considered.

A frequently unreported but critical aspect of the evaluation is serial examination done by the same person. When the diagnosis is unclear, serial abdominal examination permits the physician to decrease the number of unnecessary operations without increased risk to the patient.

Investigations: Total leukocyte count (TLC) and neutrophil count are two most important parameters. The sensitivity of TLC ranges from 52% -96% and that of left shifted neutrophil count from 39% - 96%. Left shift is more important than elevated total count. Positive values for C-reactive protein (CRP) and ESR are useful but negative values not necessarily rule out the diagnosis. Dueholm [6] found that a normal TLC, neutrophil percentage, and CRP level correctly rule out appendicitis with 100% accuracy.

Plain radiograph may be helpful. Fecaliths are present in 10% - 20% of the patients and are an indication for surgery even when the symptoms are mild.

In skilled hand, ultrasonography has proven to be an effective diagnostic aid. A prospective study showed that ultrasonography was more accurate than surgeon's initial clinical impression.

Most studies demonstrate sensitivity greater than 85% and specificity greater than 90% [7].

Computed tomography has recently been employed successfully in the diagnosis of acute appendicitis. A rapid sequence, unenhanced CT scan of the lower abdomen can accurately diagnose acute appendicitis [8]. Comparison of CT and USG has shown that the latter is more sensitive whereas the former is more specific [8,9].

Pre-operative work up for appendicitis remains a clinical diagnosis, and operation can proceed with a consistent history and physical examination alone. These diagnostic methods are only necessary if the diagnosis is unclear. Routine use of CT or USG does not substantially affect the diagnosis or clinical course of patients with acute appendicitis. Furthermore, although studies report superior results compared with single physical examination, serial examination by the same examiner is the safest and most accurate diagnostic tool.

One must remember, acute appendicitis can mimic virtually any intra-abdominal condition, and therefore to know acute appendicitis is to know well the diagnosis of acute abdominal pain.

Treatment: The most generally accepted treatment of acute appendicitis is prompt surgery, although evidence has been reported indicating that some cases of acute appendicitis can resolve spontaneously [10]. However, no studies determine the risk for developing complicated appendicitis if no initial operation is performed. There is no recognized radiological study, laboratory value, or clinical sign that helps determine which case of acute appendicitis will resolve and which will lead to complication, and this nonsurgical approach has few followers. However, there is no increased risk of perforation or incidence of complication if the surgery is delayed for 6 to 18 hours, rather than operating hastily in a suboptimal condition (middle of the night or non-resuscitated patient) [11,12,13].

Surgical approach:

Acute appendicitis: Right lower quadrant abdominal incisions have stood as gold standard approach for appendectomy for decades. In recent years, laparoscopic approach has gained wide popularity and has

been shown to improve patients' outcome in multiple reports [14,15,16,17]. It seems reasonable that the laparoscopic appendectomy should be considered at least equivalent to open surgery in today's laparoscopic era. The reported advantages of laparoscopic appendectomy, compare to open surgery, in children are similar to that of adult and include shorter hospitalization, fewer wound infection, earlier

return to normal activities, better cosmesis, more effective lavage and better visualization of the peritoneal cavity. However, its use in the management of complicated appendicitis is somewhat controversial.

Perforated appendicitis: Treatment of patients with perforated appendicitis is more complicated and controversial than that of patients with acute appendicitis. In practice, treatment is often graded according to the severity of the necrosis and the degree of abscess formation. Many factor including – social, cultural, economic, and medical, influencing the diagnosis and treatment of this disease process results in perforation rates that vary substantially from institution to institution. Perforation rate between 16% and 57% in children have been reported.

Mortality and morbidity from perforated appendicitis was very high in the recent past but has dropped dramatically at present due to the advent of newer antibiotics and prompt surgical care. The length of hospitalization and the morbidity of patients with perforated appendicitis still far exceed that of acute appendicitis. Increase rate of tubal infertility has been reported by some authors in patients with perforated appendicitis before puberty. The consensus of perforated appendicitis may be mitigated through both public and medical education that ensures prompt, early treatment before perforation.

There is no consensus on the optimum treatment of patients with a perforated appendicitis. Opinion ranges from non surgical treatment to aggressive surgical resection with antibiotic irrigation, drainage of the peritoneal cavity. But surgical treatment remains the standard approach because of the difficulty in determining before surgery whether perforation has occurred. The surgical procedure for a

perforated appendicitis is the same as that for acute appendicitis, namely removal of the appendix, accompanied by peritoneal toileting.

Appendiceal mass: Management of patients with a palpable abdominal mass has been controversial for more than 100 years. It occurs in a small but significant fraction of patients with advanced appendicitis, especially in young children after perforation. Some advocate immediate appendectomy. But majority prefers a conservative approach and interval appendectomy after 2 to 3 months and proceed to appendectomy only when the lump is discovered under anesthesia. But emergency operation becomes mandatory if the conservative measures fail. Small bowel obstruction is reported to be a sign which suggests failure of non surgical treatment [17, 18] as also persistent fever spikes and necessitates early surgery.

References:

1. Addiss DG, Shaffer N, Fowler BS, Taux RV. The epidemiology of appendicitis and appendectomy in the United States. *Am J Epidemiol* 1990; 132: 910-25.
2. Brender JD et al. Childhood appendicitis: Factors associated with perforation. *Pediatrics* 1985; 76: 301
3. Scher KS, Coil JA Jr. Appendicitis: Factors that influence the frequency of perforation. *South Med J* 1980; 73: 1561
4. Mattei P et al. Chronic and recurrent appendicitis are uncommon entities often misdiagnosed. *J Am Coll Surg* 1994; 178:385
5. Seidman JD et al. Recurrent abdominal pain due to chronic appendiceal disease. *South Med J* 1991; 84 : 913
6. Dueholm S, Bagi P, Bud M. Laboratory aid in the diagnosis of acute appendicitis; A blinded, prospective, trial concerning diagnostic value of leukocyte count, neutrophil differential count and C-reactive protein. *Dis Colon Rectum* 1989; 32:855
7. Yacoe ME, Jeffrey RB. Sonography of appendicitis and diverticulitis. *Radiol Clin North Am* 1994; 32:899
8. Malone AJ et al. Diagnosis of acute appendicitis; value of unenhanced CT. *Am J Roentgenol* 1993; 160: 763
9. Dirnbaum BA, Balthazar EJ. CT of appendicitis and diverticulitis. *Radiol Clin North Am* 1994; 32:885
10. Anderson R et al. indications for operation in suspected appendicitis and incidence of perforation. *Br Med J* 1994; 308 :107
11. Surana R, O' Donnell B, Puri P. Appendicitis diagnosed following active observation does not increase morbidity in children. *Pediatr Surg Int* 1995; 10: 76
12. Surana R, Quinn F, Puri P. Is it necessary to perform appendisectomy in the middle of the night in children? *Br Med J* 1993; 306: 1168
13. White JJ, Santillana M, Haller JA. Intensive in-hospital observation: A safe way to decrease unnecessary appendectomy. *Am Surg* 1975; 41: 793
14. Mompean JAL, Campos RR, Pericio PP et al. Laparoscopic versus open appendisectomy; A prospective assessment. *Br J Surg* 1994; 81: 133-35
15. Golub R, Siddiqui F, Pohl D. Laparoscopic versus open appendectomy: A meta analysis. *J Am Coll Surg* 1998; 186: 545-53
16. Gilchrist BF, Lobe TE, Schroop KP et al. Is there a role for laparoscopic appendectomy in pediatric surgery? *J Pediatr Surg* 1992; 27: 209-14.
17. Blakely ML, Spurpeck WW, Lobe TE. Current status of laparoscopic appendectomy in children. *Semin Pediatr Surg* 1998; 7: 225-27.
18. Bufo AJ, Shah RS, Li MH. Interval appendicectomy for perforated appendicitis in children. *J Laparoendosc Advan Surg Tech Part A* 1998; 8: 209-14.

Undescended testis

Undescended testis is defined as a testis that cannot be manipulated to the bottom of the scrotum without undue tension on the spermatic cord. Undescended testis may be palpable or impalpable. A palpable undescended testis must be differentiated from a retractile testis. Useful criteria for distinguishing a retractile testis are:

1. The testis can be brought fully to the bottom of the scrotum without difficulty.

2. The testis remains in the scrotum after manipulation without immediate retraction
3. The testis is normal in size
4. There is history that the testis resides in the scrotum spontaneously at some point of time (this may be observed during sleep)

Treatment of cryptorchidism is based on the assumption that early treatment will prevent secondary degeneration of the testis caused by high temperature. Studies have shown that early degeneration of germ cells occur in first 6 to 12 months of age. Ultrastructural electron microscopic changes occur in the second year of life, light microscopic changes in the third and fourth year and macroscopic atrophy after five years of age. The evidence that abnormality of germ maturation occur within the first year of life has led the clinician to appreciate that early intervention may prevent it. Current recommendation is to do orchiopexy between 6 and 12 months of age.

If undescended testis is detected at birth, repeat examination should be done at 3 months of age and if the testis remains undescended at 3 months, the child should be referred for orchiopexy in the second six months of life or during second year.

When the testes descend spontaneously, they should be followed up carefully for secondary ascent. If the child with undescended testis first presents beyond the recommended age, orchiopexy should be advised as early as possible.

Diagnosis and treatment:

Diagnosis of undescended testis is mainly clinical, an empty hemiscrotum and palpable testis in the groin is confirmatory. But difficulty remains when the non-descent testis is not palpable even after repeated examination. Both Ultrasonography and MRI has limited value in locating an intra-abdominal testis.

Open orchiopexy by groin exploration is the gold standard for palpable undescended testis. Though some people would prefer extended exploration for an intra-abdominal testis; laparoscopy provides excellent opportunity for both locating the testis and for laparoscopy assisted orchiopexy at the same time.

Testicular torsion

Twisting or torsion of the testis results in occlusion of the gonadal blood supply, which if unrelieved, leads to necrosis as early as 6 hours after the onset. Although it is not the most common cause of acute scrotum in children, it is the most important because delay in treatment leads to loss of testis. Intratunical or intravaginal torsion is the most common and is predisposed by high investment of the spermatic cord by the tunica vaginalis leading to, what is commonly referred to as 'bell and clapper' deformity.

Clinical presentation of testicular torsion is usually heralded by sudden onset pain in the testis, lower abdomen, or groin, associated with nausea and vomiting. Unless the testis and epididymis are necrotic, local palpation is exquisitely painful. The hemiscrotum rapidly becomes red and edematous, and, if untreated, infarction of the testis produces bluish discoloration of the hemiscrotum.

Testicular torsion should be diagnosed promptly and should be differentiated from other common acute scrotal conditions. Epididymitis (epididymo-orchitis) is rare before puberty and is likely to be associated with dysuria and evidence of urinary tract infection. Mumps virus also has a predilection for postpubertal and not for the prepubertal testis.

The presentation of idiopathic scrotal edema is similar, although the physical signs allow it to be differentiated rapidly from inflammatory conditions within the tunica. This is because the edema and redness is not confined to the hemiscrotum (Fig. 5)

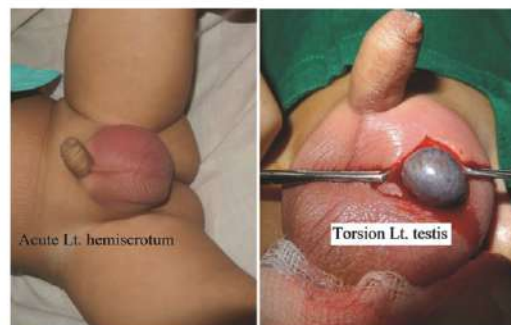

Figure 5: Acute scrotum confined to left side, exploration showing torsion.

but spread to both halves of the scrotum and even on to the adjacent tissue. By deep palpation the testis usually appears to slip between fingers but in torsion the whole hemiscrotum is felt as a firm mass.

A strangulated hernia can be readily diagnosed as a tender abdomino-scrotal swelling, usually associated with features of intestinal obstruction.

Diagnosis: Investigations such as radioisotope scan and Doppler ultrasound have been employed to determine whether there is blood flow the testis in acute scrotum. Blood flow is usually absent is torsion whereas in simple inflammation it is increased. Before puberty, however, when the testis is 1 or 2 ml in volume, such tests are of lower accuracy and have limited clinical usefulness.

Treatment : Acute hemiscrotum in a prepubertal child should be considered as torsion unless otherwise proved. And when a child presents with pain, swelling, and redness confined to hemiscrotum, immediate exploration is recommended. If the testis is twisted, this is untwisted and the viability assessed. If the testis is viable it should be preserved and fixed within the tunica to prevent recurrent torsion. If the testis is necrosed, it should be removed (Fig. 6).

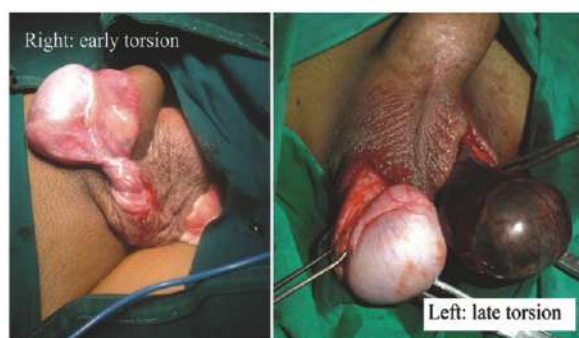

Figure 6: Early torsion (Right) with viable testis and late torsion (Left) with necrosis.

There is now good evidence that testicular ischemia damages the blood-testis barrier and exposes the child to potential risk of autoimmunization against his own spermatogonia.

The contralateral hemiscrotum should always be explored when torsion of the testis is found because the testicular anomaly is usually bilateral and the contralateral testis should be fixed within the tunica with non-absorbable sutures.

Gall stones in Children

Gall bladder disease is one of the most common and most costly diseases that require hospitalization in United States. Gall bladder calculi (stones) are relatively more common in the adult population and remain relatively uncommon in children, but have been increasingly diagnosed in the recent years mainly because of widespread use of ultrasonography. The prevalence of gallstones among adult population in the West is 10% to 20% [1,2] and this figure in India is 3% to 6% [3,4]. . Studies from Europe have shown an overall prevalence of gallstone disease of 0.13% to 0.2% in children (5,6). In Japan, the prevalence of gallstone disease is reported to be less than 0.13% of children (7). The only report from India by Ganesh, et al. has shown a prevalence of 0.3% in a hospital based observation among 13,675 children (8).

How it forms?

Biliary sludge (mud) is the beginning point of gall stone formation. This sludge is commonly associated with prolonged fasting, total parenteral nutrition, pregnancy, haemolytic disease, treatment with ceftriaxone, octreotide, and frusemide and phototherapy [9]. Ceftriaxone is a popular drug among paediatricians for its broad spectrum antimicrobial activity and is used mainly for enteric fever (typhoid) and central nervous system infections (meningitis). But ceftriaxone induced stone formation is reversible and usually disappears after discontinuation of treatment. Octreotide is used in pancreatitis and frusemide for some renal (kidney), and heart disease. Natural history of this sludge is unpredictable; it may resolve completely or may progress to proper stone formation.

Causative factors : Etiologically [5,10] gall stones in children can be divided into three groups; (i) hemolytic, (ii) other known etiology, and (iii) idiopathic (unknown). Almost 20% to 30% of all gallstones in children are due to haemolytic diseases such as sickle-cell disease, hereditary spherocytosis and thalassemia. In around 40% to 50% of cases, gallstones are due to another known etiology such as total parenteral nutrition, prolonged fasting, intestinal disease or intestinal resection, frusemide therapy, congenital biliary diseases such as choledochal cyst, chronic liver disease. Around 30% to 40% of cases are idiopathic (no definite known

cause) as in adults. But there is a changing trend, now-a-days more and more childhood cholelithiasis is idiopathic as in adult. Or it may be said as change in age not the etiology.

Symptoms:

Gall stones in infants and children may be silent or symptomatic. Children with gallstones can present with acute abdominal pain due to cholecystitis, cholangitis or pancreatitis. However, an acute presentation is uncommon. Most commonly, children with gall stones present with typical right upper abdominal pain (50%), or nonspecific abdominal symptoms (25%), including poorly localized abdominal pain and feeling for vomiting. Around 20% of cases are asymptomatic (incidentally detected stones). Abdominal ultrasonography for UTI frequently detects gall stones in children. Gallstones in children are more often symptomatic than in adult. The type of symptoms depend on the age of presentation, older children often localize pain in the right upper abdomen whereas younger children (5 years or less) tend to present with nonspecific symptoms. Fatty food intolerance, a typical symptom of gallstone disease in adults, tends to be reported by older children.

Diagnosis:

The universally used and the most accurate diagnostic test in detecting the presence of gallstones is ultrasonography. Gallstones are usually mobile, single or multiple and characteristically cast an acoustic shadow. Biliary sludge though appearing echogenic on ultrasound, does not cast an acoustic shadow. A stone, as small as 1.5 mm, can be detected by ultrasonography. Complicated cases need advanced investigation like MRI, nuclear imaging and endoscopy.

Treatment:

Management of gallstones depends on the symptoms and the age of the patient. Those with typical symptoms (right upper abdominal pain, nausea, vomiting and fatty food intolerance) should have their gallbladders removed. Symptomatic gallstones need cholecystectomy (operative removal of gall bladder) and same is true for complicated gallstones but there is no consensus about the management of asymptomatic gallstones in children. Some believe that asymptomatic children or children with

nonspecific symptoms can undergo safe follow up. Once they develop typical symptom or complication, need operation; otherwise they need indefinite follow up till they remains asymptomatic or till stones resolves spontaneously. But there remains risk of stone slipping into bile passage causing obstruction to the bile flow into the intestine and making the treatment more complicated unless the stones pass spontaneously into the intestine.

Once parents come to know about the stones, it produces constant parental worry and they tend to attribute any symptoms of the child to the gall stones. School teachers also react in a similar way and send the child home frequently on forced leave on slightest symptoms.

In recent years, laparoscopic operation has become the treatment of choice in the surgical management of gall stones in children. It has the advantage of being less invasive with quick recovery and shorter hospital stay over conventional open operation. It can be done in as young as one year of age.

Fetal gall stone:

Gall stones have been detected in babies even before birth (Fetal gall stone). These need confirmation by ultrasonography after birth. Most of these stones disappear spontaneously. The approach to gall stone in infancy is different as spontaneous resolution has been reported in a significant proportion of cases. Spontaneous resolution within 6 months is more common with idiopathic gallstones than in patients with known predisposing factors. The prognosis of fetal gallstones is very good as complete spontaneous resolution has been documented in the majority of cases between 1 and 12 months after birth and those that persist are rarely symptomatic (11).

Trials to dissolve gall stone by medicine (Urso deoxy cholic acid) are on. But available results are disappointing [12]. It incurs recurrent cost for prolonged treatment and even if there is temporary dissolution of stones; recurrence is common.

References:

1. Rome Group for the Epidemiology and Prevention of Cholelithiasis (GREPCO). The Epidemiology of gallstone disease in Rome, Italy. Part I. Prevalence data in men. *Hepatology* 1988; 8: 904-906.

2. Bainton D, Davies GT, Evans KT, Gravelle IH. Gallbladder disease. Prevalence in a South Wales Industrial Town. *N Engl J Med* 1976; 294: 1147- 1149.
 3. Khuroo MS, Mahajan R, Zargar SA, Javid G, Sapru S. Prevalence of biliary tract disease in India: a sonographic study in adult population in Kashmir. *Gut* 1989; 30: 2001-2005.
 4. Singh V, Trikha B, Nain CK, Singh K, Bose SM. Epidemiology of gallstone disease in Chandigarh: A community-based study. *J Gastroenterol Hepatol* 2001; 16: 560-563.
 5. Wesdorp I, Bosman D, de Graaff A, Aronson D, van der Blij F, Taminiau J. Clinical presentations and predisposing factors of cholelithiasis and sludge in children. *J Pediatr Gastroenterol Nutr* 2000; 31: 411-417.
 6. Palasciano G, Portincasa P, Vinciguerra V, Velardi A, Tardi S, Baldassarre G, et al. Gallstone prevalence and gallbladder volume in children and adolescents: an epidemiological ultrasonographic survey and relationship to body mass index. *Am J Gastroenterol* 1989; 84: 1378-1382.
 7. Nomura H, Kashiwagi S, Hayashi J, Kajiyama W, Ikematsu H, Noguchi A, et al. Prevalence of gallstone disease in a general population of Okinawa, Japan. *Am J Epidemiol* 1988; 128: 598-605.
 8. Ganesh R, Muralinath S, Sankarnarayanan VS, Sathiyasekaran M. Prevalence of cholelithiasis in children – a hospital-based observation. *Indian J Gastroenterol* 2005; 24: 85.
 9. Hussaini SH, Pereira SP, Veysey MJ, Kennedy C, Jenkins P, Murphy GM, et al. Roles of gall bladder emptying and intestinal transit in the pathogenesis of octreotide induced gall bladder stones. *Gut* 1996; 38: 775-783.
 10. Schweizer P, Lenz MP, Kirschner HJ. Pathogenesis and symptomatology of cholelithiasis in childhood. *Dig Surg* 2000; 17: 459-467.
 11. Suma V, Marini A, Bucci N, Toffolutti T, Talenti E. Fetal gallstones: sonographic and clinical observations. *Ultrasound Obstet Gynecol* 1998; 12: 439-441.
 12. Gamba PG, Zancan L, Muraca M, Vilei MT, Talenti E, Guglielmi M. Is there a place of medical treatment in children with gallstones? *J Pediatr Surg* 1997; 32: 476-478.
-



Dr. Rajesh Kumar Barooah

Associate professor, Neurosurgery
CN Centre, GMC

J Assoc Surg of Assam 2023;1 : 31-35

JASA

The Journal of Association of
Surgeons of Assam
Volume 30, No. 1
June 2023 to October 2023

Head injury: Prognosticators- and Basic Management

Traumatic brain injury (TBI) is a disease process that carries major public health and socioeconomic consequences. Due to the high rate of death and morbidity, a patient with a head injury is a nightmare for the public in general and the neurosurgeon in particular. With a population of above 30 million and the ever increasing traffic, Assam also has its burden of head injury. Moreover, a considerable proportion of TBI survivors incur temporary or permanent disability.

In order to decrease more lives lost to traumatic brain injury and to prevent morbidity and mortality steps need to be taken right from the primary level till referral if warranted to the higher centers.

Assessment using GCS: The Glasgow Coma Scale (GCS) was introduced forty years ago by Teasdale and Jennett as a practical method for assessing the full spectrum of disorders of consciousness, from very mild to severe. The GCS aims to rate performance in three different domains of response: the eye, verbal, and motor response. A score of ≥ 13 correlates with a mild brain injury, 9 to 12 is a moderate injury, and ≤ 8 a severe brain injury. To compare evaluations over time or when speaking with other healthcare professionals, standardized techniques to both its assessment and its reporting are necessary.

Assessment and stabilization of airway: In the setting of acute head injury, priority should be given to the immediate assessment and stabilization of the airway and circulation. Despite the fact that prehospital intubation has become common, at least one study has reported a higher rate of mortality in patients intubated in the field than in those intubated in the hospital setting. In this study, however, more critically ill patients required in-field intubation¹.

Transport of patients: Patients with a GCS of 15 with minimal involvement of other systems may be observed without immediate referral. Patients with a GCS of Head injury: Prognosticators- and Basic Management less than 13, with age less than 15 years or greater than 65 years of age should be rapidly transported directly from the scene to the highest level trauma center available to allow for expedient neurosurgical assessment and intervention. Care should be taken during transport especially of the cervical spine and the head.

Prevention of secondary head injury: Next, attention should be directed to prevention of secondary injury. Mean arterial pressures should be kept above 90 mm Hg so as to maintain Cerebral perfusion pressure. Arterial saturations should be greater than 90%. Urgent CT scan is a priority.

Management of raised Intracranial Pressure (ICP):

Attention should be focused on reducing intracranial pressure, since elevated intracranial pressure is an independent predictor of poor outcome. Management can be structured on the basis of three tiers mentioned as below²

TIER 1:

1. Head of bed elevated at 30 degrees (reverse Trendelenburg) to improve cerebral venous outflow.
2. Sedation and analgesia using recommended short-acting agents (for example, propofol, fentanyl, midazolam) in intubated patients.
3. Ventricular drainage performed intermittently. Continuous drainage is not recommended unless an additional ICP monitor is placed, as when the drain is open, it does not accurately reflect the true ICP.
4. Repeat CT imaging and neurological examination should be considered to rule out the development of a surgical mass lesion and guide treatment.

If ICP remains $\geq 20 - 25$ mmHg, steps mentioned under Tier 2 may be adopted.

TIER 2:

1. In patients with a parenchymal ICP monitor an EVD should be considered to allow for intermittent CSF drainage

2. Hyperosmolar therapy should be given intermittently as needed for ICP elevation and not on a routine schedule

► Mannitol should be administered in intermittent boluses (0.25 -1 gm/kg body weight). Caution should be taken in the hypovolemic patient when osmotic diuresis is instituted with mannitol. The serum sodium and osmolality must be assessed frequently (every 6 hours) and additional doses should be held if serum osmolality exceeds 320 mOsm/L.

► Hypertonic saline may be administered in intermittent boluses of 3% sodium chloride solution (250 ml over ½ hour) or other concentrations (e.g., 30cc of 23.4%). Serum sodium and osmolality must be assessed frequently (every 6 hours) and additional doses should be held if serum sodium exceeds 160 mEq/L.

3. PaCO₂ goal of 30 - 35 mmHg should be maintained, as long as brain hypoxia is not encountered.

4. CT head may be repeated at this stage to detect any mass lesion that may need surgical evacuation in case ICP remains elevated.

TIER 3:

1. Decompressive hemi-craniectomy or bilateral craniectomy should only be performed if treatments in Tiers 1 and 2 are not sufficient or are limited by development of side effects of medical treatment. DECRA trial concluded that in adults with severe diffuse traumatic brain injury and refractory intracranial hypertension, early bifronto-temporo-parietal decompressive craniectomy decreased intracranial pressure and the length of stay in the ICU but was associated with more unfavorable outcomes³

2. Neuromuscular paralysis via continuous infusion of a neuromuscular blocking agent can be employed if there is a positive response to a bolus dose

3. Barbiturate or propofol (anesthesia dosage) coma may be induced for those patients who have failed to respond to aggressive measures to control malignant intracranial hypertension, however it should only be instituted if a test dose of barbiturate or propofol results in a decrease in ICP⁴.

4. Hypothermia (<36 °C) is not currently recommended as an initial TBI treatment. Hypothermia should be reserved for "rescue" or salvage therapy after reasonable attempts at ICP control via the previous Tier3 treatments have failed. Although hypothermic therapy initially appeared promising, and despite the fact that hypothermia decreases intracranial pressure, a large randomized study of 392 patients with head injuries

recently demonstrated that hypothermic therapy does not improve outcomes. In addition, a post-hoc analysis found that the rewarming of patients with head injury who arrived in the emergency department already hypothermic was likely detrimental^{5,6}

Surgical management :⁷ Surgery for TBI patients is most commonly performed to evacuate epidural hematomas (EDH), subdural hematomas (SDH), cerebral contusions, or intracerebral hematomas (ICH) that are large enough to cause significant mass effect on the brain. Surgical evacuation of these hematomas should be performed as soon as possible. Admitted patients who undergo neurological deterioration from delayed development or enlargement of a hematoma require prompt surgical evacuation to prevent further neurological worsening. Traditionally, the prompt surgical evacuation of subdural hematomas in less than 4 hours was believed to be a major determinant of an optimal outcome. Indeed, a recent publication found a delay in surgery for acute subdural hematomas of over 5 hours was associated with increased mortality⁸ Nevertheless, other recent investigations have emphasized that the extent of the original intracranial injury and the generated intracranial pressures may be more important than the timing of surgery. Frontal parenchymal hematomas are more likely to require eventual surgery. Depressed skull fractures are commonly elevated if the depression is greater than the depth of the adjacent inner table, especially if located in a cosmetically important area like the forehead. Open depressed fractures are best treated surgically to prevent infection, but non-operative management may be attempted in selected cases, limited to those without dural laceration, gross contamination or evidence of infection, or injury to the frontal sinus. In general, a depressed skull fracture over the sagittal sinus should not be treated surgically because of the high risk of uncontrollable hemorrhage.

Nutritional support :⁹⁻¹³ Nutrition should begin early, as soon as the patient is hemodynamically stable, and ideally within 24-48 hours of injury. This recommendation is made in conjunction with the Brain Trauma Foundation recommendation of

achieving full nutritional support within 7 days of injury. When considering nutrition support, enteral nutrition is recommended over the use of parenteral nutrition. If parenteral nutrition use is unavoidable, frequent glucose monitoring must be performed to insure that the patient remains euglycemic.

Timing of pharmacologic venous thromboembolism prophylaxis: Patients with TBI are at high risk for venous thromboembolism (VTE), with rates as high as 20-30%. In spite of these risks, providers have traditionally erred on the side of withholding pharmacologic VTE prophylaxis, accepting a higher risk of a VTE event in order to prevent potential progression of intracranial hemorrhage following TBI. Evidence suggests that delay in initiation of > 4 days after injury substantially increases the risk of VTE, so balancing these risks is critical. VTE prophylaxis should be considered within the first 72 hours following TBI in most patients. Earlier initiation of pharmacologic prophylaxis (<72 hours) appears to be safe in patients at low risk for progression of intracranial bleeding and have a stable repeat head CT scan¹⁴⁻¹⁶

Antiepileptic therapy: Anticonvulsant therapy, if used, should be discontinued after 1 - 2 weeks unless further seizures supervene¹⁷.

Outcome assessment of patient should be done at 3 months or 6 months preferably using Glasgow Outcome Scale (GOS).

The operative and non-operative management of intracranial injuries is an ever-evolving area of study and, at present, more a matter of neurosurgical judgment than hard and fast decision rules. Traumatic brain injury patient should receive the utmost level of care to prevent longstanding disability post recovery. With the present day sophistication in daily life head injury is likely to increase, predominantly due to lack of awareness regarding road safety or blunt refusal to adhere to it. A loss of life in productive year is a loss not only to the family but the country as a whole. Strict application of road safety measures and public awareness to it is a key to reduce road traffic accidents.

REFERENCES:

1. Wang HE, Peitzman AB, Cassidy LD, et al. Out - of - hospital endotracheal intubation and outcome after traumatic brain injury. *Ann Emerg Med.* Nov 2004; 44 (5): 439 - 50. [Medline]
2. Brain Trauma Foundation; American Association of Neurological Surgeons; Congress of Neurological Surgeons; Joint Section on Neurotrauma and Critical Care, AANS/CNS, Bratton SL, Chestnut RM, Ghajar J, McConnell Hammond FF, Harris OA, Hartl R, Manley GT, Nemecek A, Newell DW, Rosenthal G, Schouten J, Shutter L, Timmons SD, Ullman JS, Videtta W, Wilberger JE, Wright DW. Guidelines for the Management of Severe Traumatic Brain Injury. VI. Indications for Intracranial Pressure Monitoring. *J Neurotrauma*, 24 Suppl 1:S37-44, 2007
3. Cooper DJ, Rosenfeld JV, Murray L et al. Decompressive Craniectomy in Diffuse Traumatic Brain Injury. *N Engl J Med* 2011; 364: 1493 - 1502. DOI: 10.1056/NEJMoa1102077
4. Roberts I. Barbiturates for acute traumatic brain injury. *Cochrane Database Syst Rev.*2000; CD000033. [Medline].
5. Clifton GL, Miller ER, Choi SC, et al. Lack of effect of induction of hypothermia after acute brain injury. *N Engl J Med.* Feb 22 2001; 344 (8): 556 - 63. [Medline]
6. Sydenham E, Roberts I, Alderson P. Hypothermia for traumatic head injury. *Cochrane Database Syst Rev.*Apr/2009; 15: CD001048
7. Bullock RM, Chesnut R, Ghajar JBG, Gordon D, Hartl R, Newell DW, Servadei, F, Walters, BC, Wilberger JE. Guidelines for the Surgical Management of Traumatic Brain Injury. *Neurosurgery, Supplement, Volume 58, Number 3.* 2006.
8. Zhao H, Bai XJ. Influence of operative timing on prognosis of patients with acute subdural hematoma. *Chin J Traumatol.* Oct/2009; 12: 296 - 8.
9. Hartl, R., et al., Effect of early nutrition on deaths due to severe traumatic brain injury. *J Neurosurg* 109:50-6. 2008
10. Chiang, Y.H., et al., Early enteral nutrition and clinical outcomes of severe traumatic brain injury patients in acute stage: a multi-center cohort study. *J Neurotrauma*, 29:75-80. 2012
11. Wang, X., et al., Nutritional support for patients sustaining traumatic brain injury: a systematic review and meta-analysis of prospective studies. *PLoS One*, 8:e58838. 2013
12. Brain Trauma Foundation, American Association of Neurological Surgeons; Congress of Neurological Surgeons; Joint Section on Neurotrauma and Critical Care, AANS/CNS, Bratton SL, Chestnut RM, Ghajar J, McConnell Hammond FF, Harris OA, Hartl R, Manley GT, Nemecek A, Newell DW, Rosenthal G, Schouten J, Shutter L, Timmons SD, Ullman JS, Videtta W, Wilberger JE, Wright DW. Guidelines for the Management of Severe Traumatic Brain Injury. XII. Nutrition. *J Neurotrauma*. 24 Suppl 1:S77-82, 2007.
13. Dhaliwal R, Cahill N, Lemieux M, Heyland DK. The Canadian critical care nutrition guidelines in 2013: an update on current recommendations and implementation strategies. *Nutr Clin Pract.*, 29:29-43. 2014
14. ACCP guidelines Bernstein IH, Pruitt J, Butler G, Rogers L, Minei JP. TBI risk stratification at presentation: a prospective study of the incidence and timing of radiographic worsening in the Parkland Protocol. *J Trauma Acute Care Surg.* 2012 Aug;73(2 Suppl 1):S122-7.
15. Farooqui A, Hiser B, Barnes SL, Litofsky NS. Safety and efficacy of early thromboembolism chemoprophylaxis after intracranial hemorrhage from traumatic brain injury. *J Neurosurg.* 2013 Dec;119(6): 1576-82. doi: 10.3171/2013.8.JNS13424. Epub 2013 Sep 20. PubMed PMID: 24053504

16. Jamjoom AA, Jamjoom AB. Safety and efficacy of early pharmacological thromboprophylaxis in traumatic brain injury: systematic review and meta-analysis. *J Neurotrauma*. 2013 Apr 1;30(7):503-11
 17. Temkin NR, Dikmen SS, Anderson GD, et al. Valproate therapy for prevention of posttraumatic seizures: a randomized trial. *J Neurosurg*. Oct 1999; 91 (4): 593 - 600. [Medline].
-

Case Report



A Case Report on a Rare Case of Teratoma Involving Adrenal Gland

Dr. Faridul Hussian

Dr. Prabal Deka

Department of General Surgery,
Dewcare Hospital Center,
Nagaon, Assam

J Assoc Surg of Assam 2023;1 : 36-38

JASA

The Journal of Association of
Surgeons of Assam
Volume 30, No. 1
June 2023 to October 2023

ABSTRACT

Teratomas are germ cell tumors which are mainly gonadal in origin. Other common extra-gonadal sites are mediastinal, sacro-coccygeal and pineal regions. Retroperitoneal teratoma is rare and comprises of about 1% of all teratomas, Adrenal teratomas are extremely rare (1). Adrenal teratomas form about 0.13% of all adrenal tumours. We reported a case of primary adrenal teratoma in a 13 year old female child who presented with a large adrenal teratoma which was nonfunctional bio-chemically and underwent surgical excision, along with its clinical features, symptoms during the course of disease, also about its diagnosis and treatment part. We reviewed literature from 2000 to till date, and found 29 adult cases and 6 paediatric cases of adrenal teratoma. Usually, they are asymptomatic and identified as an incidental finding. Imaging modality such as USG, CT and MRI are useful in diagnosis⁽¹⁾. Though these tumors are mostly benign, malignant transformation may occur⁽²⁾. Treatment includes surgical removal. The purpose of this reporting is to share our experience with diagnosis and treatment of primary adrenal teratoma, in order to determine the clinical characteristics associated with this rare tumor.

Introduction

Teratomas are tumor stemming from embryonal germ layers that are mainly composed of pluripotent stem cells. Teratomas are very rare and uncommon, whose incidence is 0.9/100,000 among the population⁽¹⁾. The majority of teratomas are mature and contain multiple layers of embryonic germ cell layer, therefore, teratomas may contain skin, hair, teeth, brain tissue, nerves, adipose tissue, cartilage, and so forth⁽³⁾. Based on the original locations of a teratoma, the most common sites of occurrence are the gonads⁽⁴⁾, with extra-gonadal sites including the anterior mediastinum, retroperitoneum, sacrococcygeal region, pineal gland, and suprasellar region⁽⁵⁾. Among the retroperitoneal teratomas, primary adrenal teratomas are extremely rare. Extra-gonadal teratomas are uncommon tumors and are less common in adults than children.

These are mostly retroperitoneal in location. Moreover, primary adrenal teratomas are even rarer. Diagnosing of adrenal teratomas is a challenge as these mimic myelolipomas, angiomyolipomas or liposarcomas⁽¹⁾. These tumors are mostly benign, whereas malignant transformation may occur more often in adults than children, thus becoming an important entity that requires appropriate management protocol. Here, we discuss such a case of primary adrenal teratoma identified in a young female of age 13 years. Also, a literature review regarding adrenal teratoma in adult and paediatric population published from 2000 till date, which were available on the internet, was performed.

Case Report

A 13-year-old female child presented to hospital with progressive abdominal distension, right flank pain and a palpable lump over right upper abdomen which was increasing in size since 5 months. Pain was colicky in nature and was relieved by medication. The patient had no history of weight loss or fever. There was no significant past or family history. There was a palpable mass spreading over right hypochondrium, epigastrium, and right lumbar region of approximate size 15cm x 12cm x 12cm in size, intraperitoneal, partially cystic and mobile. On evaluation with ultrasound, there was a heterogeneous solid-cystic lesion with a predominantly cystic component seen in the right suprarenal region to inferior margin of liver. Contrast enhanced CT (CECT) of the abdomen revealed a large 14.2cm x 12.8cm x 11.9cm in axial and craniocaudal dimensions, well marginated, multiloculated, complex cystic lesion situated in retroperitoneum on the right side. The lesion contains predominantly fluid density contents along with long bone, soft tissue with fat attenuation within the cystic cavity in the right suprarenal region, anteriorly displacing the right lobe of liver, suprarenal IVC is seen to course along the anterior border of the lesion with mild luminal narrowing, inferiorly abutting and indenting the superior pole of right kidney, right suprarenal gland could not be visualized separately. Medially closely abutting the portal vein and uncinate process of pancreas. Concluding as a giant primary retroperitoneal teratoma. The endocrine workup for adrenal

tumour was normal. Tumour markers which included Alpha Fetoprotein (AFP), Human Chorionic Gonadotropin (HCG) and Lactate Dehydrogenase (LDH) were within normal limits. Physical examination and routine investigations were done including blood pressure and complete blood count all were within normal limits.

The child underwent explorative laparotomy and intraoperatively a large mass was seen replacing and pressing on the right kidney. Dense adhesions were present between tumour and retroperitoneal abdominal wall, inferior surface of liver and lateral wall, medially there was dense adhesions with portal vein, no invasion of any other major blood vessels noted. Mass was well encapsulated and no infiltration of normal renal parenchyma was seen. Left adrenal and bilateral ovaries were normal. Complete surgical resection of tumor was done along with right adrenalectomy without any intraoperative or postoperative complications. The specimen was sent for histopathological examination. On gross examination cystic mass with tooth and bone like areas and hair tuft was seen. On microscopic examination cells from all three germ layers were seen, residual compressed adrenal cortical tissue was evident in the wall of cyst. Final diagnosis of mature cystic teratoma of adrenal gland was made. After surgery, the child had an uneventful recovery and she is still on follow-up, there is no abdominal distension on clinical examination and no recurrent lesion on ultrasonography.

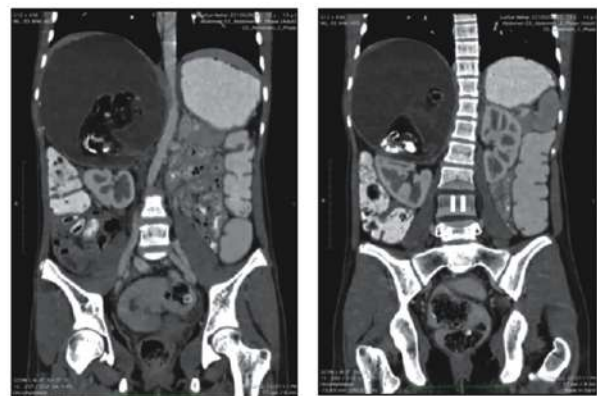

Image1: CECT abdomen in coronal plane shows displacement of right kidney with heterogeneously hyperdense internal contents and rim like peripheral calcification.

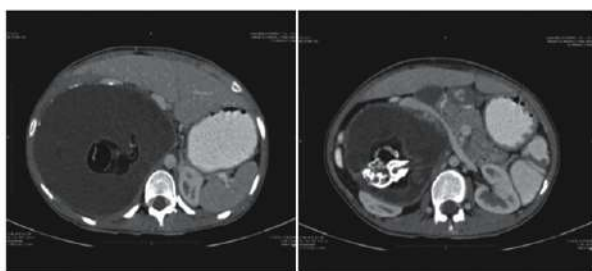


Image 2: Contrast enhanced CT (CECT) abdomen in axial plane showing well-defined lesion on right suprarenal location with intralesional fatty attenuation and bony elements .

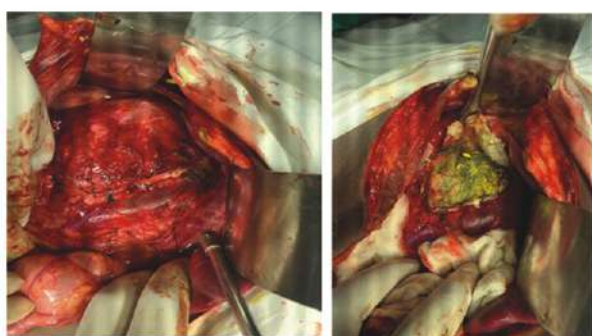


Image 3: Intraoperative pictures showing heterogeneous mass during surgical resection.

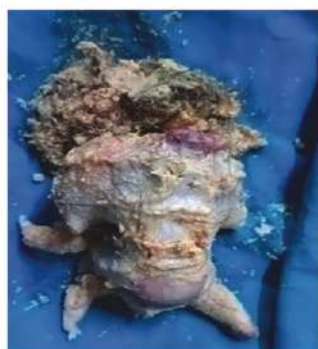

Image 4: Cut surface of resected globular soft cystic mass, showing cheesy whitish pultaceous material along with hair, bone and cartilage.

Conclusion

We have described the features of imaging, pathology, and the treatment of the typical primary adrenal teratoma to further raise people's awareness of this rare disease, and primary adrenal teratomas should be included in the differential diagnosis of adrenal masses. The purpose of this article is to identify

characteristic imaging features of teratoma and differentiating between the various lipomatous lesions involving adrenal region. Although adrenal teratoma is a rare tumor, it is essential to understand and acknowledge its characteristic features and to make an appropriate diagnosis. Its characteristic features help in identifying and distinguishing them from similar characteristic adrenal lesions. This eventually helps in appropriate line of management and better prognosis.

REFERENCES

1. Ban A, Satapara J, Rathod K, Bahri N. Teratoma involving adrenal gland—A case report and review of literature. *Indian Journal of Radiology and Imaging*. 2019 Oct;29(04): 452-6.
2. Gatcombe HG, Assikis V, Kooby D, Johnstone PA. Primary retroperitoneal teratomas: a review of the literature. *Journal of surgical oncology*. 2004 May 1;86(2): 107-13.
3. Zhou L, Pan X, He T, Lai Y, Li W, Hu Y, Ni L, Yang S, Chen Y, Lai Y. Primary adrenal teratoma: A case series and review of the literature. *Molecular and Clinical Oncology*. 2018 Oct 1;9(4):437-42.
4. Shintani Y, Funaki S, Nakagiri T, Inoue M, Sawabata N, Minami M, Kadota Y, Okumura M. Experience with thoroscopic resection for mediastinal mature teratoma: a retrospective analysis of 15 patients. *Interactive cardiovascular and thoracic surgery*. 2013 Apr 1;16(4): 441-4.
5. Wang X, Li X, Cai H, Xiao W, Su P, Huang X, Luo X, Zhang N, Fu N. Rare Primary Adrenal Tumor: A Case Report of Teratomas and Literatures Review. *Frontiers in Oncology*. 2022;12.

Case Report

A Rare Presentation of Chronic Cholecystitis - Cholecystocutaneous Fistula-A Case Report



Dr. Bibhu Priyo Das

Assistant Professor of Surgery,
Tezpur Medical College, Tezpur

Dr. Subash A Ragupathy

PGT, Dept of Surgery,
Tezpur Medical College, Tezpur

J Assoc Surg of Assam 2023;1 : 39-42

JASA

The Journal of Association of
Surgeons of Assam
Volume 30, No. 1
June 2023 to October 2023

ABSTRACT : Spontaneous cholecystocutaneous fistula is a rare presentation of chronic calculous cholecystitis, which is usually neglected. We present such a case of a 54 year old female, with unusual presentation of expulsion of stones from a fistulous tract in the right upper abdomen, which was diagnosed as cholecystocutaneous fistula, which was treated by diagnostic laparoscopy followed by laparoscopic cholecystectomy and excision of the fistulous tract.

INTRODUCTION:

Among the presentations of chronic calculous cholecystitis, spontaneous extra-biliary fistula remains a rare presentation. Biliary fistula refers to the formation of an abnormal tract between the gallbladder and adjacent epithelial surfaces, which could be the gastrointestinal tract (internal fistula) or the abdominal wall (external fistula). External fistula formation may be spontaneous, post-traumatic, or iatrogenic in origin ⁽²⁾. The first case of cholecystocutaneous fistula was reported in literature by Thileus in 1760⁽¹⁾ and till date less than 100 cases have been reported. We report a case of spontaneous Cholecystocutaneous fistula following chronic cholecystitis treated successfully by Laparoscopic cholecystectomy.

CASE PRESENTATION:

A 54 years old female presented to the casualty department with severe pain in right upper abdomen with expulsion of stones from an opening in the right upper abdomen for the past 1 day. She was a diagnosed case of chronic calculous cholecystitis for the past 7 years for which she had refused surgery and was on treatment with oral painkillers. With every episode of pain, for the past 1 year she noticed an opening in the right upper abdomen which was insidious in onset, and was progressively increasing in size. She gave a history of several episodes of serous discharge from the opening during every severe attack of pain and later for the last 3 months she noticed discharge of stones through the same opening with every attack, after which the pain resolved. After initial resuscitation and pain management the patient was admitted for further investigation. The vitals at the time of admission were normal.

On examination, an opening approximately measuring 0.5cm x 0.5cm was noted in the right hypochondrium, circular in shape with serous discharge. Some amount of induration was also noticed over the skin around the opening.

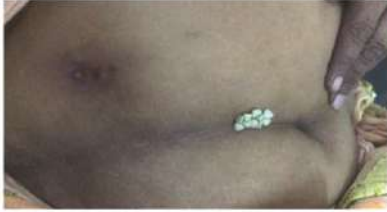

Fig 1: Fistulous tract opening in the right hypochondrium with the expelled gall stones.

The initial routine blood investigations were within normal range and initial USG whole abdomen was inconclusive. The CECT whole abdomen was done and it revealed an contacted gallbladder with a defect in the fundus of the gallbladder forming an fistulous tract communicating to the exterior in the right anterolateral aspect of the abdominal wall, with the fistulous tract having a cystic dilatation in the muscular and subcutaneous plane in the abdomen with no Calculi within the Gb.

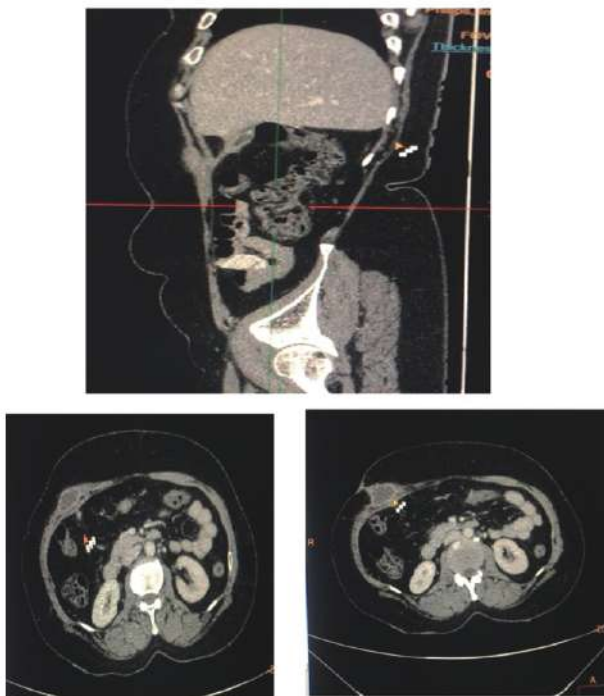
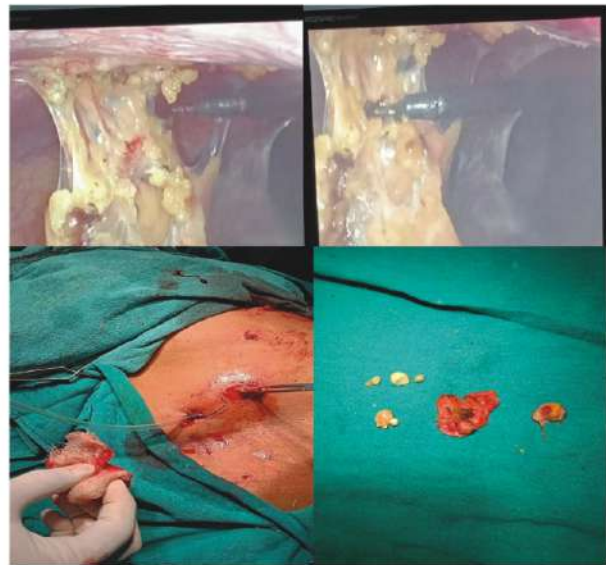

Fig 2: CT sections demonstrating communication between the gallbladder and the abdominal wall.

With the radiological evidence and after an sound pre operative preparation, the patient was taken up for elective surgery. Intra operatively, densely adhered gall bladder with the abdominal wall was identified. The patient underwent laparoscopic cholecystectomy with fistulous tract excision.

Post operative period was uneventful and patient was followed up for one year with no complication.

A histological examination confirmed the diagnosis of chronic cholecystitis with gallstones and cholecystocutaneous fistula.



DISCUSSION :

Biliary fistulas refer to the formation of an abnormal tract between the gallbladder and adjacent epithelial surfaces, which could be the gastrointestinal tract (internal fistula) or the abdominal wall (external fistula). Internal fistulas are much more common, 75% of them connecting to the duodenum and 15% to the colon. The remaining 10% of internal fistulas connect with the stomach or jejunum, or have multiple communications such as cholecysto-duodenocolic fistula⁽³⁾. External biliary fistulas are rare. This disease mainly affects female subjects over the age of 60. Etiology is generally due to an acute inflammatory process as a consequence of a cholecystitis or chronic gallstones disease ⁽⁴⁻⁷⁾. However, there are described cases of spontaneous cholecystocutaneous fistula in the absence of gallstones.⁽⁸⁾ Cases of Cholecystocutaneous fistula

have been reported following cholangiocarcinoma and carcinoma Gall bladder.^(6,9,10) The external opening of a cholecystocutaneous fistula is generally in the right hypochondrium. However, other sites can be involved such as the left hypochondrium (45%), the umbilicus (27%), the right lumbar region, the right iliac fossa and the gluteal region.^(11,12) External fistulas have been reported as a result of the chronic perforation of the gallbladder, and obstruction of the cystic duct by a stone plays an important role in the pathophysiology of perforation; adherence to the abdominal wall and necrosis of the gallbladder lead to fistula formation.⁽¹³⁾ Fistula primum movens is by cystic duct obstruction, which increases the pressure within the gallbladder, with wall distension and impaired vascularisation, resulting in the formation of focal necrosis of the wall with perforation. Fundus is the most distant from the cystic artery and physiologically the least vascularised and therefore more susceptible to ischemia⁽¹⁴⁾. The typical presentation of a persistent discharging sinus should suggest the diagnosis, particularly in an elderly patient with a previous history of gallstones or jaundice^(15,16). The imaging techniques that can guide diagnosis are USG and CT fistulogram ^(17,18). The management of an external biliary fistula clearly depends on the underlying etiology.^(6,19,20) In a few proportion of patients the external biliary fistula will heal spontaneously, and therefore operation may be avoided if the patient is elderly or very debilitated. Possible surgical options include cholecystostomy with removal of the gallstones or cholecystectomy. As cholecystostomy carries the possibility of further stone formation in the gallbladder, cholecystectomy is usually the treatment of choice.^(13,21) Laparoscopic cholecystectomy and excision of the fistula confers the advantages of shorter hospital stay and shorter convalescence. An open approach is usually favoured, although a laparoscopic technique has been described by Malik et al.⁽²²⁾

CONCLUSION:

Cholecystocutaneous fistula is rare complication of neglected chronic calculous cholecystitis. Laproscopic cholecystectomy with fistulous tract excision is an effective treatment option available.

Bibliography:

- 1) Lofgren DH, Vasani S, Singzon V. Abdominal wall abscess secondary to cholecystocutaneous fistula via percutaneous cholecystostomy tract. *Cureus*. 2019;11(4): e4444. <https://doi.org/10.7759/cureus.4444>.
- 2) Dadoukis J, Prousalidis J, Botsios D, et al. External biliary fistula. *HPB Surg*. 1998;10(6):375–7. <https://doi.org/10.1155/1998/42791>.
- 3) Gibson TC, Howat JM. Cholecystocutaneous fistula. *The British Journal of Clinical Practice*. 1987 Oct 1;41(10):980-2.
- 4) Ugalde Serrano P, Solar García L, Miyar de León A, et al.: [Cholecystocutaneous fistula as a first sign of presentation of a gallbladder adenocarcinoma]. *Cir Esp*. 2013;91(6):396–397. 10.1016/j.ciresp.2011.12.009 [PubMed] [CrossRef] [Google Scholar]
- 5) Zanghì G, Leanza V, Vecchio R, et al.: Neoplastic sigmoid-uterine fistula. An exceptional complication of large intestine cancer. *G Chir*. 2017;38(1):37–40. [PMC free article] [PubMed] [Google Scholar]
- 6). Kuo YC, Wu CS: Spontaneous cutaneous biliary fistula: a rare complication of cholangiocarcinoma. *J Clin Gastroenterol*. 1990;12(4):451–453. [PubMed] [Google Scholar]
- 7) Birch BR, Cox SJ: Spontaneous external biliary fistula uncomplicated by gallstones. *Postgrad Med J*.1991;67(786):391–2. 10.1136/pgmj.67.786.391 [PMC free article] [PubMed] [CrossRef] [Google Scholar]
- 8) Sibakoti YC, Basnet RB, Poudel R: Spontaneous Cholecystocutaneous Fistula: A Case Report. *PMJM*. 2012;12(1):51–54. Reference Source [Google Scholar]
- 9) Micu BV, Andercou OA, Micu CM, et al.. Spontaneous cholecystocutaneous fistula as a primary manifestation of gallbladder adenocarcinoma associated with gallbladder lithiasis - case report. *Rom J Morphol Embryol* 2017;58:575–83. [PubMed] [Google Scholar]

- 10) Hoffman L, Beaton H, Wantz G. Spontaneous cholecystocutaneous fistula: a complication of neglected biliary tract disease. *J Am Geriatr Soc* 1982;30:632–4. 10.1111/j.1532-5415.1982.tb05059.x [PubMed] [CrossRef] [Google Scholar]
- 11) Sayed L, Sangal S, Finch G. Spontaneous Cholecystocutaneous Fistula: A Rare Presentation of Gallstones. In: *JSCR*. 2010.
- 12) Pezzilli R, Barakat B, Corinaldesi R, Cavazza M. Spontaneous Cholecystocutaneous Fistula. *Case Rep Gastroenterol*. Sep 15 2010;4(3):356-360.
- 13) Davies MG, Tadros E, Gaine S, McEntee GP, Gorey TF, Hennessy TP: Combined internal and external biliary fistulae treated by percutaneous cholecystolithotomy. *Br J Surg* 1989;76:1258.
- 14) Ugalde Serrano P, Solar García L, Miyar de León A, et al.: [Cholecystocutaneous fistula as a first sign of presentation of a gallbladder adenocarcinoma]. *Cir Esp*. 2013;91(6):396– 397. 10.1016/j.ciresp.2011.12.009 .
- 15) Andley M, Biswas RS, Ashok S, Somshekar G, Gulati SM. Spontaneous cholecystocutaneous fistula secondary to calculous cholecystitis. *Am J Gastroenterol*. 1996;91:1656–7
- 16) Czerniak A, Blumgart LH. Czerniak A, Blumgart LH. Churchill Livingstone; Edinburgh: 1994. External biliary fistula, *Surgery of the Liver and Biliary Tract*, vol 1.
- 17) Carragher AM, Jackson PR, Panesar KJ. Subcutaneous herniation of gall-bladder with spontaneous cholecystocutaneous fistula. *Clin Radiol* 1990;42: 283–4. 10.1016/S0009-9260(05)82120-8 [PubMed] [CrossRef] [Google Scholar]
- 18). Singh A, Bansal S. Human gall-bladder communicating with skin: rare anatomical swerve. *J Clin Diagn Res* 2013;7:2321–2. 10.7860/JCDR/2013/5902.3514 [PMC free article] [PubMed] [CrossRef] [Google Scholar]
- 19) Morissey KP, McSherry CK. Czerniak A, Blumgart LH. Churchill Livingstone; Edinburgh: 1994. Internal biliary fistula and gallstone ileus, *Surgery of the Liver and Biliary Tract*, vol 1.
- 20). Smith EEJ, Bowley N, Allison DJ, Blumgart LH. The management of post-traumatic intrahepatic cutaneous biliary fistulas. *Br J Surg*. 1982; 69:317–18.
- 21) Reed MWR, Tweedie JH. Spontaneous simultaneous internal and external biliary fistulae. *Br J Surg*. 1985;72:538.
- 22) Malik AH, Nadeem M, Ockrim J. Complete laparoscopic management of cholecystocutaneous fistula. *Ulster Med J* 2007;76:166–7. [PMC free article] [PubMed] [Google Scholar]
-

A Rare Case Report of Retroperitoneal Schwannoma

**Dr. Ravi Shankar S**

Surgical Resident, GMCH

Dr. Hiranmoy Das

Assistant Prof., Dept of Surgery, GMCH

Dr. Rajesh Kumar BarooahAsso. Prof., Dept of Neuro Surgery,
GMCH**Dr. Ridip Mazumder**

SR, Dept. of Surgery, GMCH

J Assoc Surg of Assam 2023; 1 : 43-44

JASAThe Journal of Association of
Surgeons of Assam
Volume 30, No. 1
June 2023 to October 2023**Introduction:**

Schwannomas are benign mesenchymal tumours that arise from Schwann cells of peripheral nerve sheaths. Commonly involved sites are head, neck and extremities. Only 1%–3% of schwannomas are found in the retroperitoneum.

CLINICAL DETAILS: A 25yr old female, presented with complaints of gradually progressive, severe low back ache with left S1 radiculopathy for 3 months.

INVESTIGATION

CEMRI PELVIS: T1- hypointense, t2 heterogenously hyperintense, well defined lesion noted in retroperitoneum(towards left), arising from S1-S2 neural foramina (extending from S2 to S5 vertebra) measuring approximately 5.6 x 5.4 x 5.7 cu cm.

TREATMENT

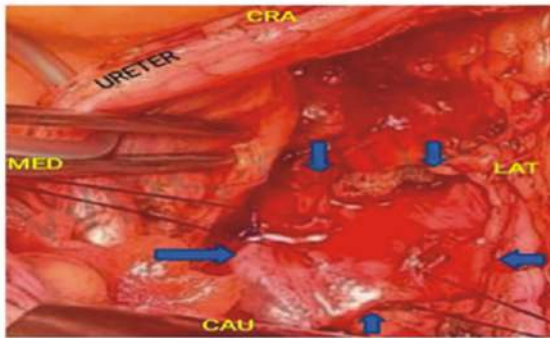
TUMOUR- EMBOLISATION: In order to decrease the vascularity, tumor embolisation by fibrin glue was performed by interventional radiology team.

OPERATIVE- PROCEDURE : Exploratory Laparotomy and gross total excision of tumor was done. Lower sigmoid colon and rectum mobilized was dissected to gain access to retro peritoneal tumor. Tumour was soft to firm, friable, moderately vascular which was removed in piecemeal manner by suction and curettage. Haemostasis achieved by bipolar diathermy & fibrillar.

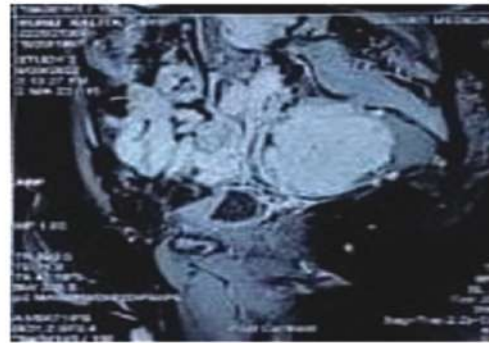
During the post operative period, patient had symptomatic improvement and was discharged on POD3 without any new neurological deficits. Histopathology of specimen showed presence of antoni A and B cells , positive to S-100 suggestive of schwannoma.

DISCUSSION

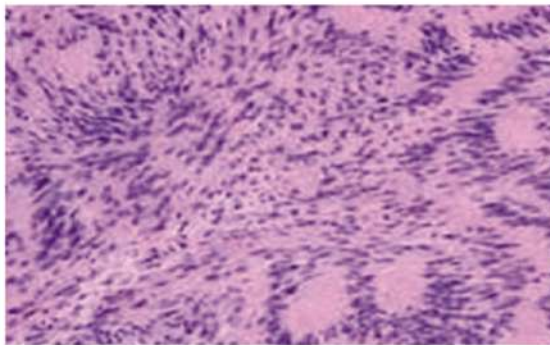
Retroperitoneal Schwannomas(RS) is usually clinically silent and needs to reach a significant size to cause symptoms. Hence, preoperative diagnosis is often difficult. MRI with GAD is the imaging modality of choice for diagnosis. Schwannomas are usually benign tumors, and scarcely undergo malignant transformation unless they are associated with von Recklinghausen's disease that accounts for 5% to 18% of all RSs. The differential diagnosis include neurogenic tumors such as paraganglioma and pheochromocytoma



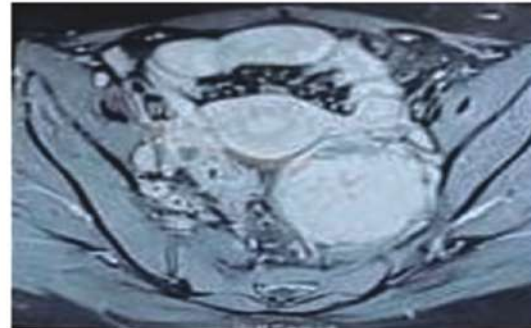
Picture1: Intra-operative SOL



Picture 2: MRI



Picture 3:HPE of the specimen



Picture 4: MRI

CONCLUSION: Retroperitoneal schwannomas are rare tumors. They are mostly benign, but can rarely be malignant, especially when associated with neurofibromatosis.

REFERENCES:

1. Harhar M, Ramdani A, Bouhout T, et al. (February 20, 2021) Retroperitoneal Schwannoma: Two Rare Case Reports. *Cureus* 13(2): e13456. doi:10.7759/cureus.13456
2. Zhang L, Gao M, Zhang T, Chong T, Wang Z, Liu W, Li H. Surgical management of retroperitoneal schwannoma complicated with severe hydronephrosis: A case report. *Medicine (Baltimore)*. 2018 Sep; 97(39):e12528.
3. Meșină C, Mogoantă SȘ, Cristian DA, Dumitrescu TV, Drăgoescu PO, Meșină-Botoran MI, Ciurea ME, Ghiluși MC, Ciobanu D. Retroperitoneal ancient schwannoma-case presentation. *Rom J Morphol Embryol*. 2015 Jan 1;56(4):1517-22.

Best Wishes For MID-TERM CME,2023,Tezpur.

SURGI ENDO WORLD

Progressive Innovation

❖ **DEALS WITH ADVANCED LAPAROSCOPIC SURGERY EQUIPMENTS & INSTRUMENTS.**

- **General Surgery**
- **Oncology**
- **Gynaecology**
- **Ortho Instruments**
- **Neuro Surgery Instruments**
- **Probes, Cables & other Accessories.**

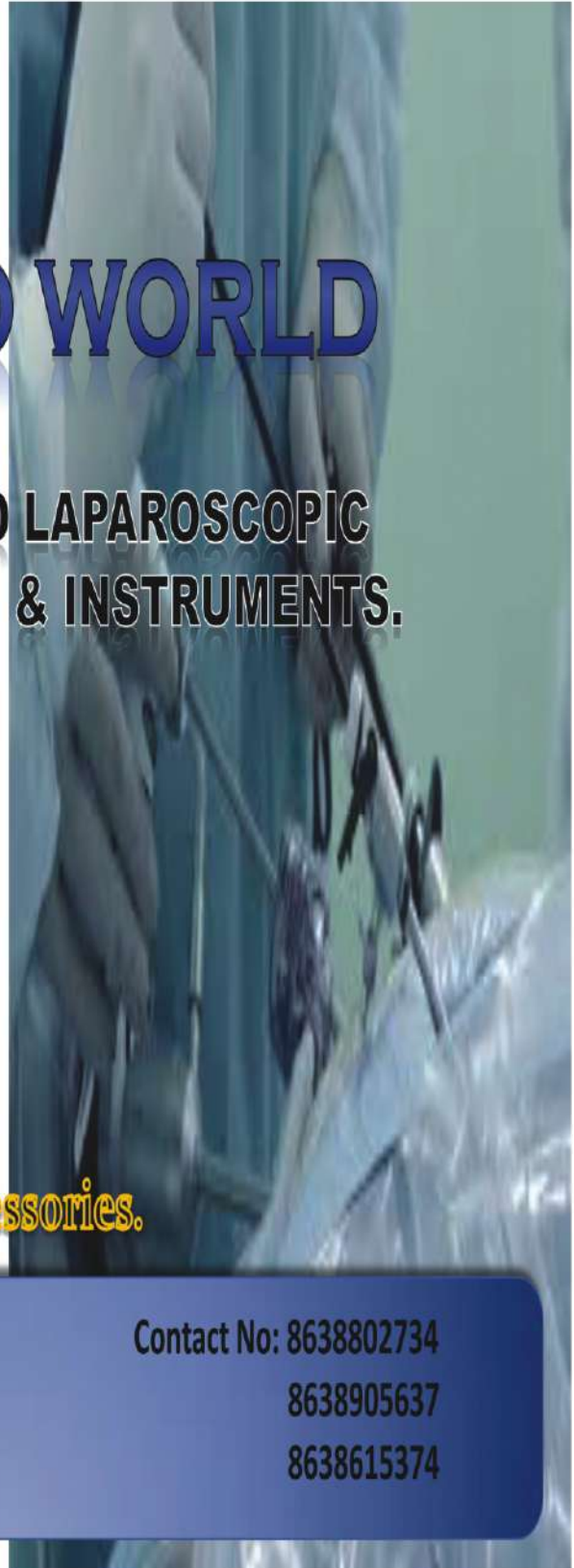Address: House no-32, Saurav Nagar, Beltola
Guwahati-28, Assam.

Email : surgiendoworld16@gmail.com

Contact No: 8638802734

8638905637

8638615374



JASA

The Journal of
Association of Surgeons of Assam
